

OZPP module - Practicum No. 3

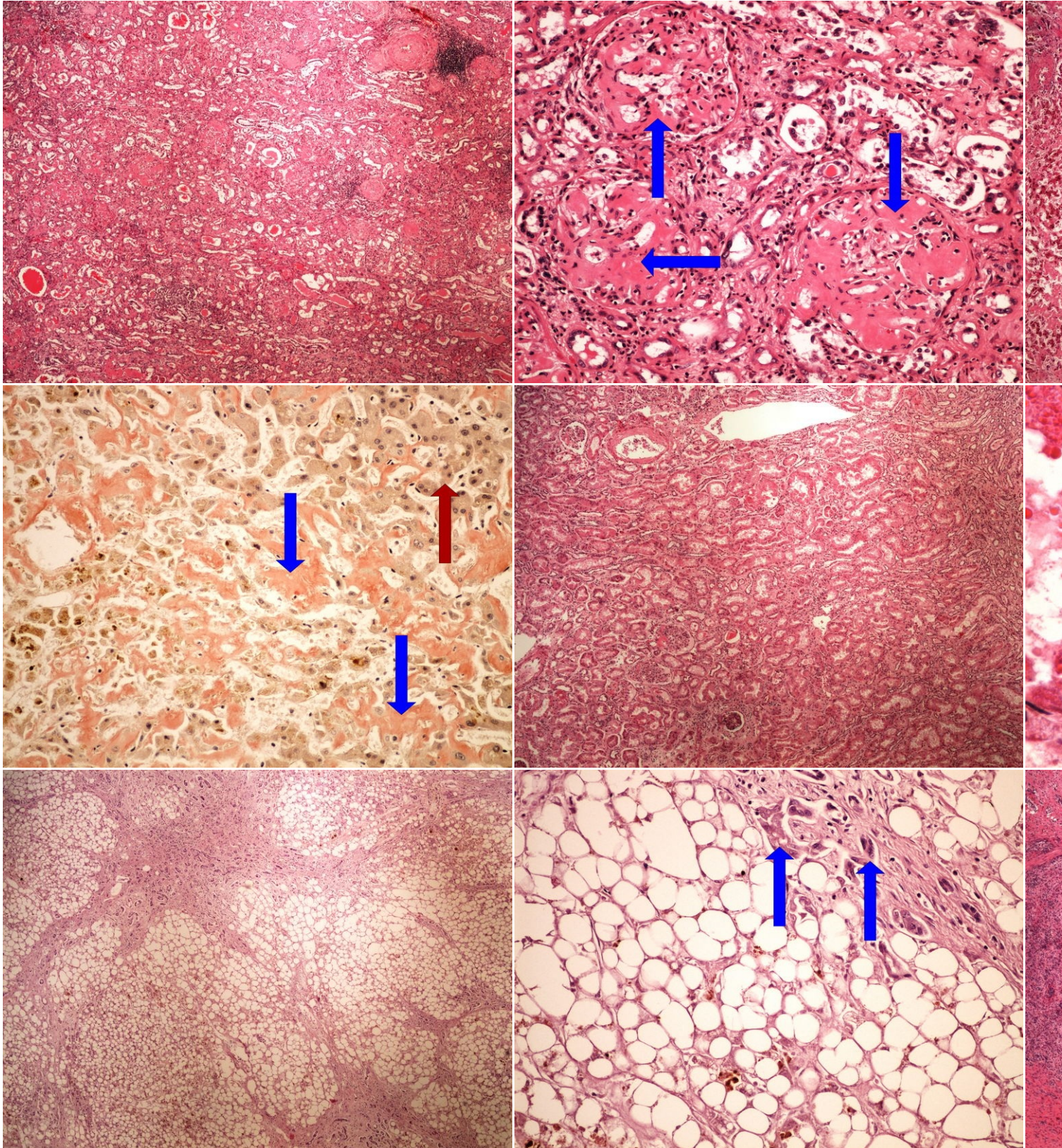
This article was checked by pedagogue

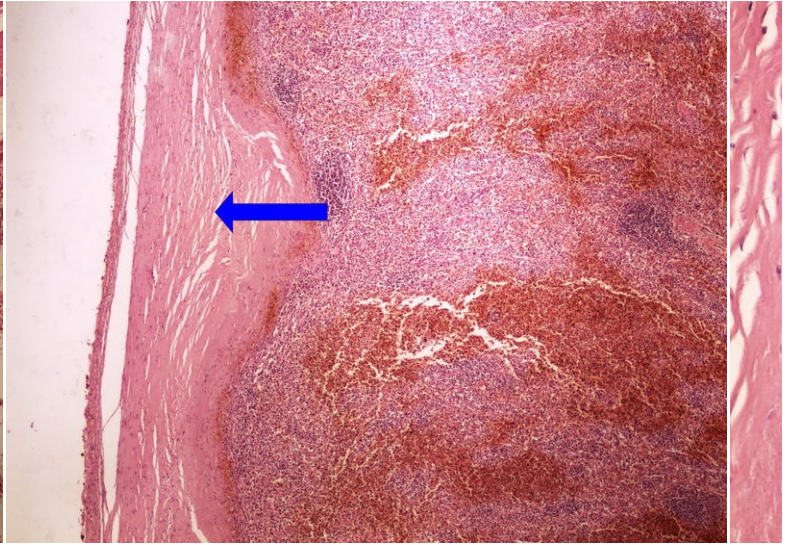
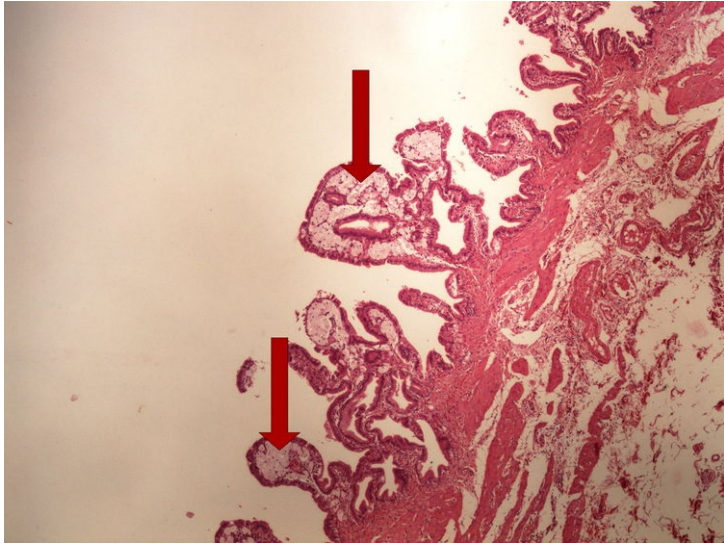
This article was checked by pedagogue, but later was changed.



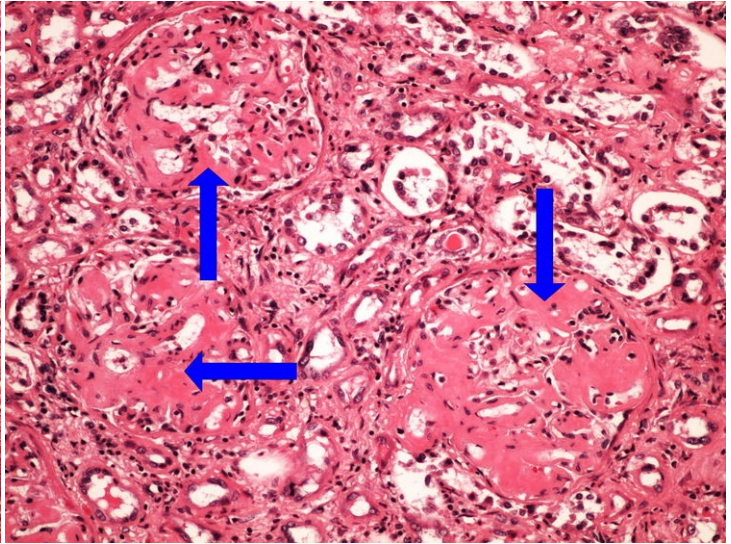
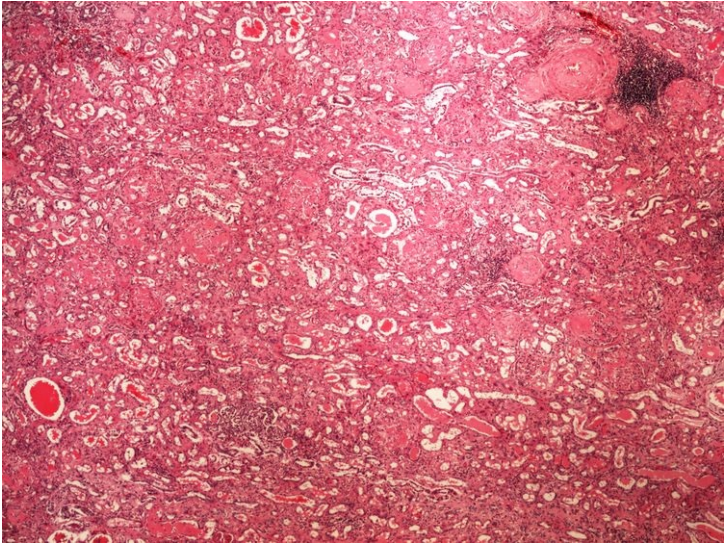
Checked version of the article can be found here (https://www.wikilectures.eu/index.php?title=OZPP_module_-_Practicum_No._3&oldid=374896).

See also comparison of actual and checked version (https://www.wikilectures.eu/index.php?title=OZPP_module_-_Practicum_No._3&diff=-&oldid=374896).



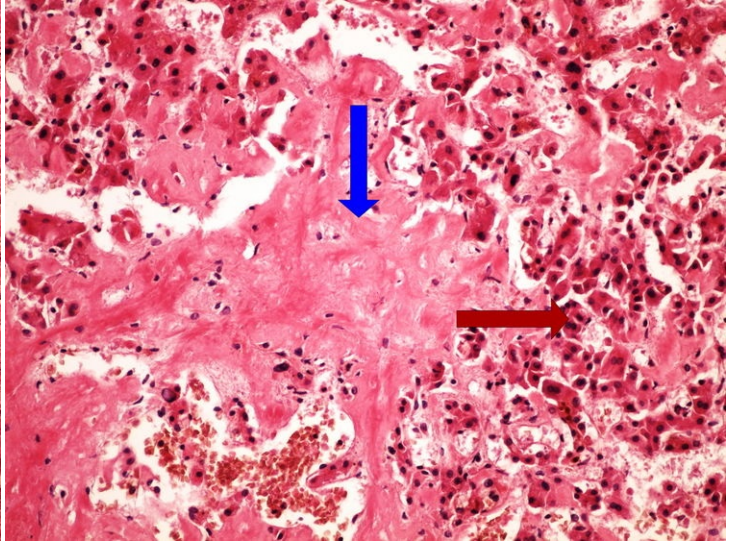
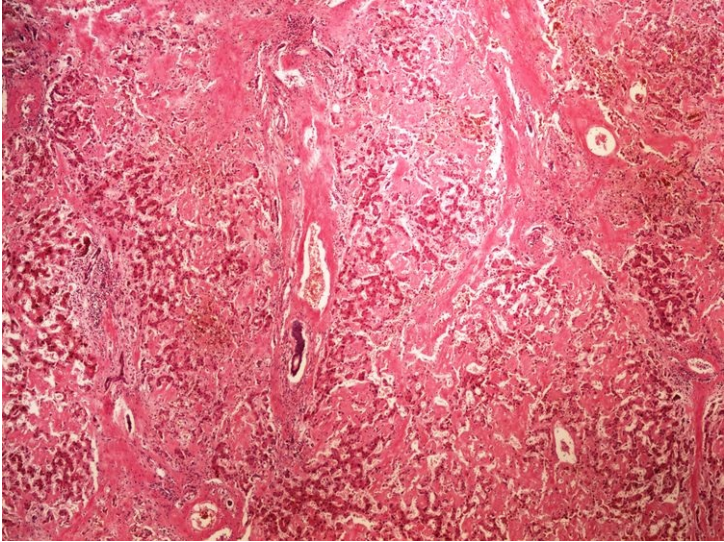


Preparation No. 1 and No. 2 - kidney amyloidosis (HE)



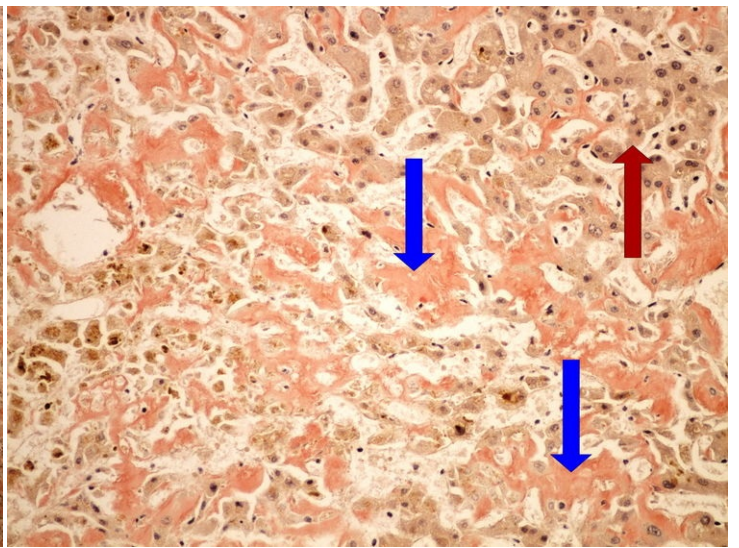
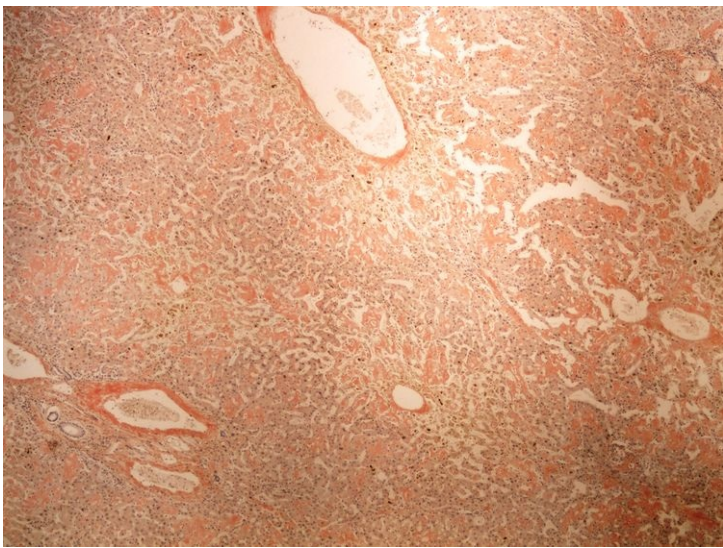
Structures [\[Expand\]](#)

Preparation No. 3 and No. 4 - liver amyloidosis (HE)



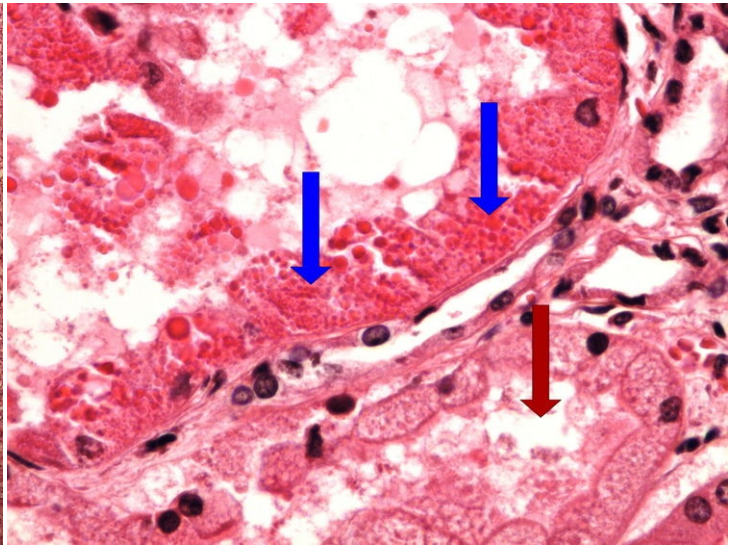
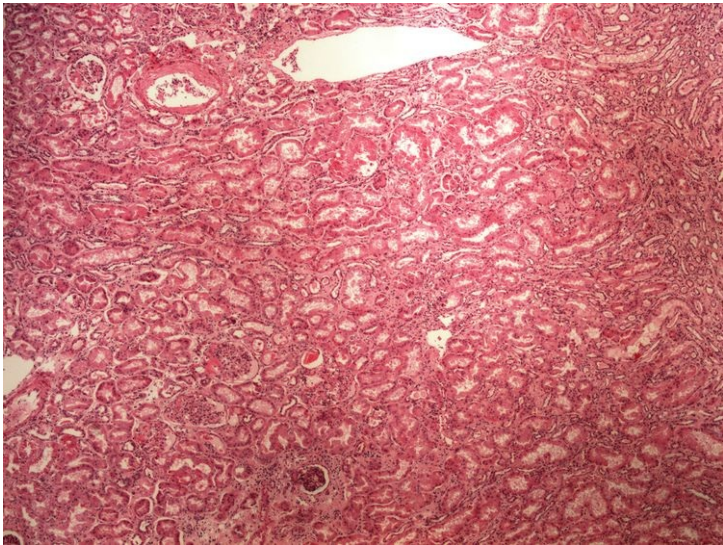
Structures [\[Expand\]](#)

Preparation No. 5 and No. 6 - amyloidosis of the liver (Congo red)



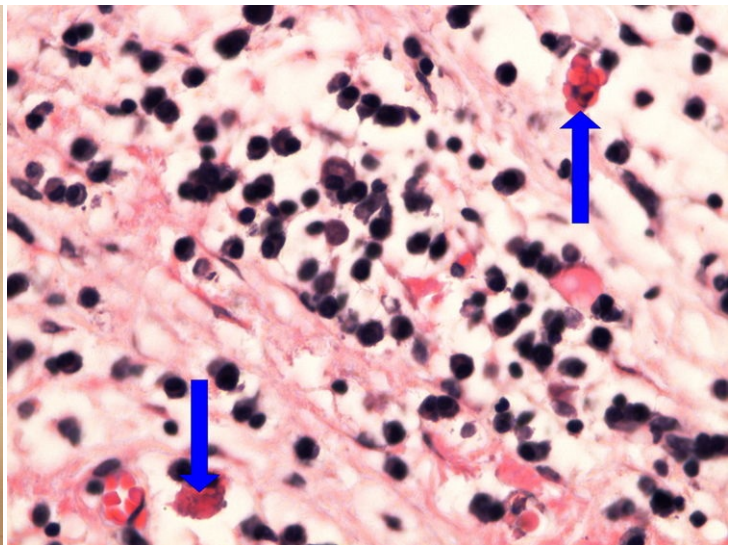
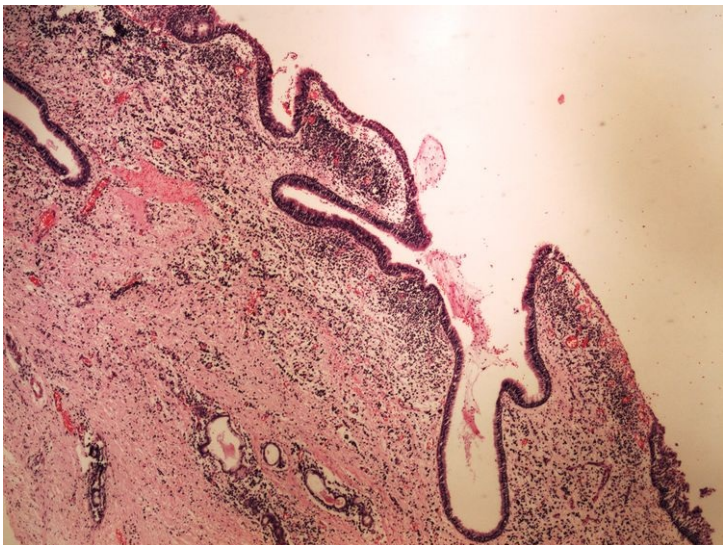
Structures [Expand]

Preparation No. 7 and No. 8 - hyaline ossification of the kidney



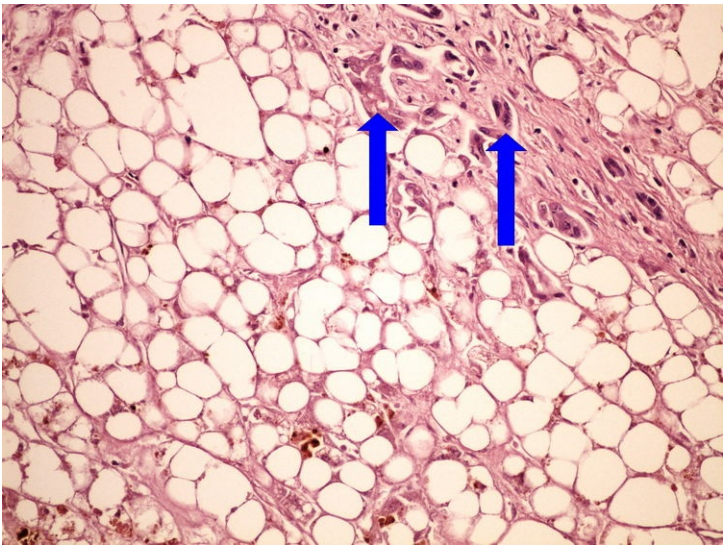
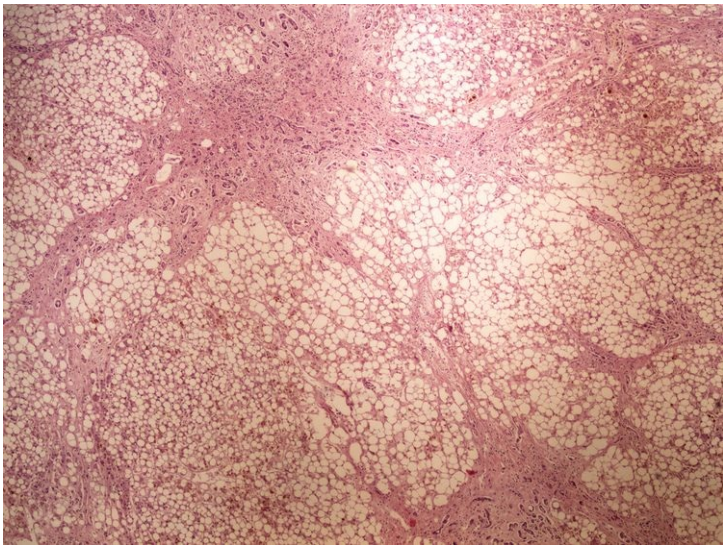
Structures [Expand]

Preparation No. 9 and No. 10 - Russel's corpuscles



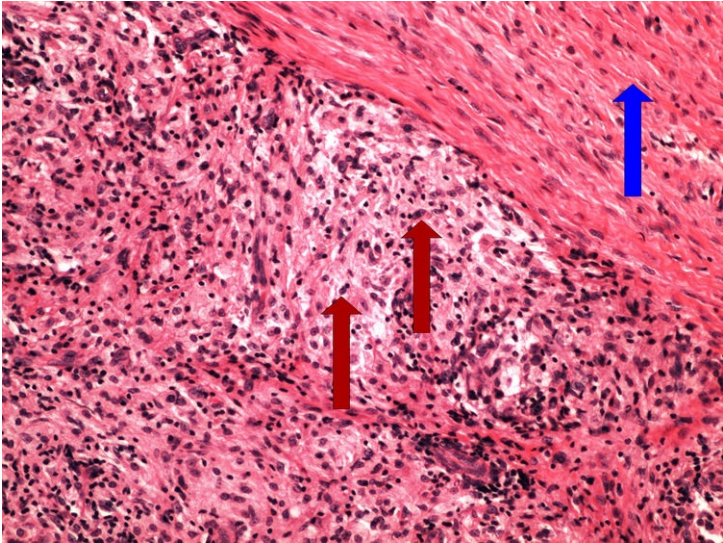
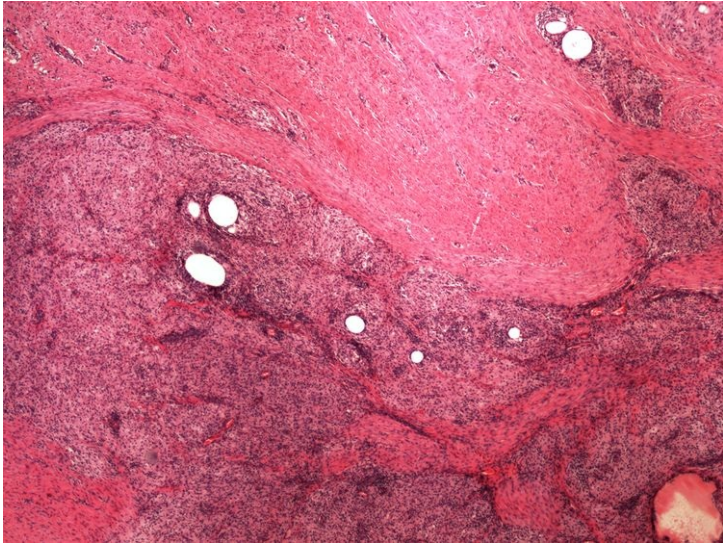
Structures [Expand]

Preparation No. 11 and No. 12 - steatosis of the liver



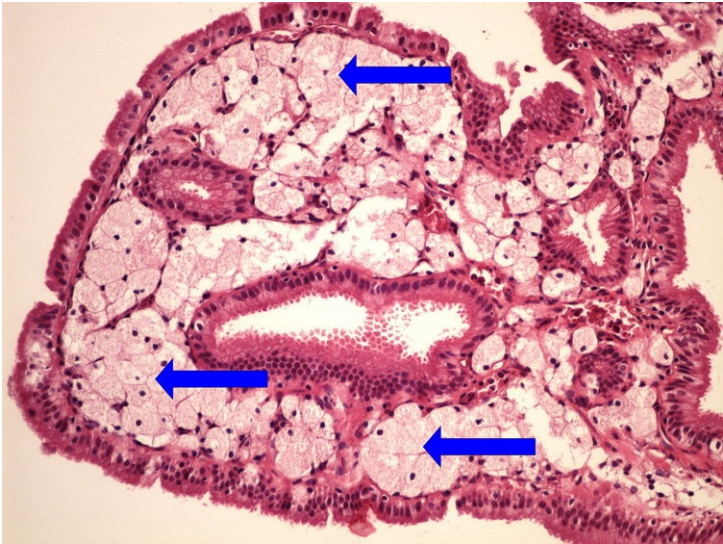
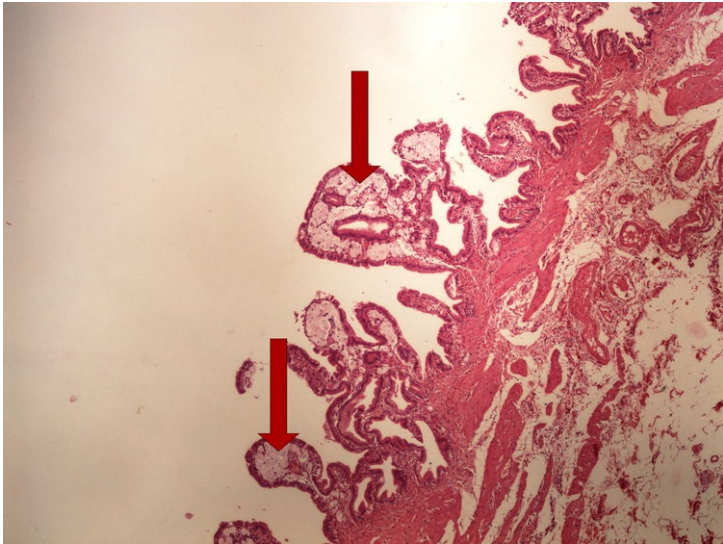
Structures [Expand]

Preparation No. 13 and No. 14 - inflammatory pseudoxanthoma



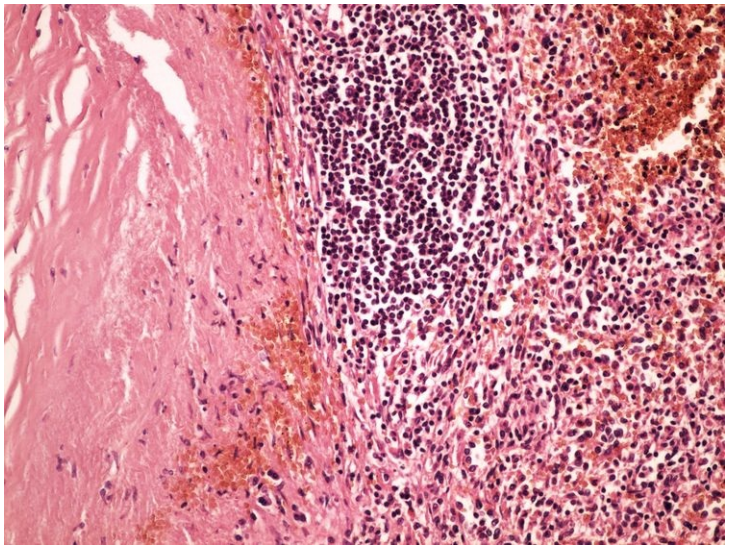
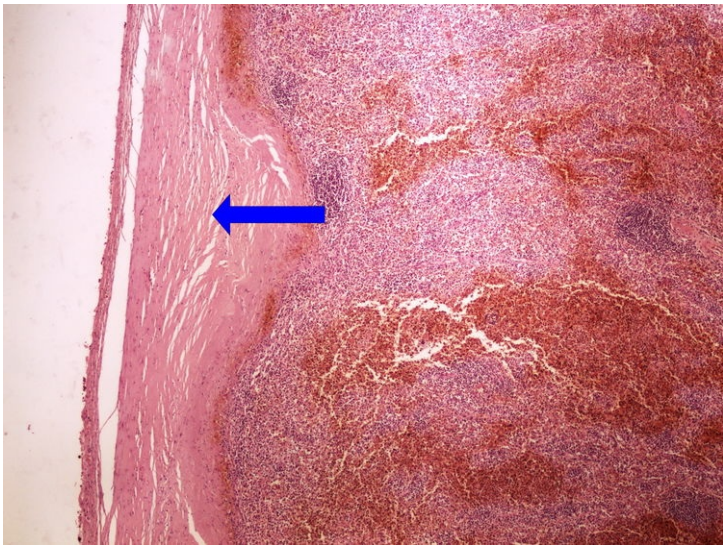
Structures [Expand]

Preparation No. 15 and No. 16 - cholesterolosa of the gallbladder



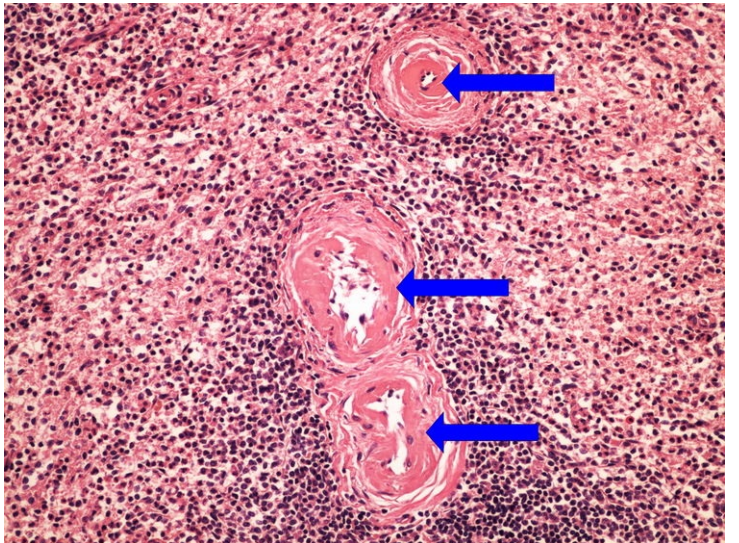
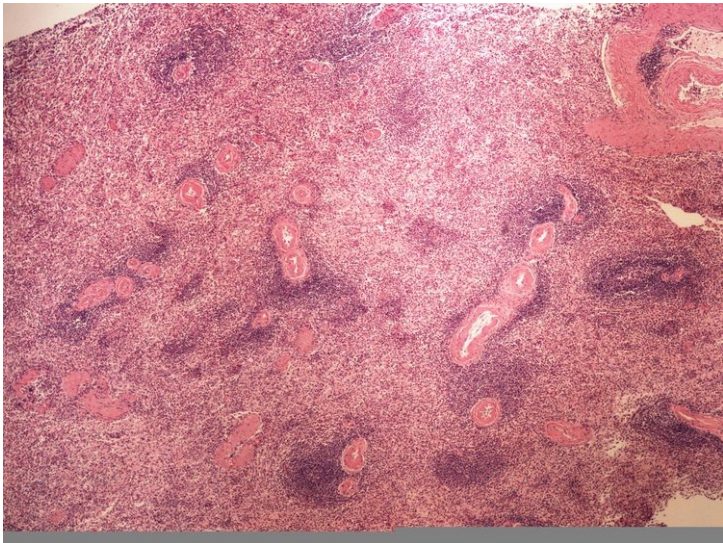
Structures [Expand]

Preparation No. 17 and No. 18 - perisplenitis cartilaginea



Structures [Expand]

Preparation No. 19 and No. 20 - fibrinoid dystrophy



Structures [Expand]

Links

Navigace

← OZPP module - Practicum No. 2

Module General basics of pathology and pathophysiology (3rd Faculty of Medicine UK)

OZPP module - Practicum No. 4 →