

# Non-specific intestinal inflammations

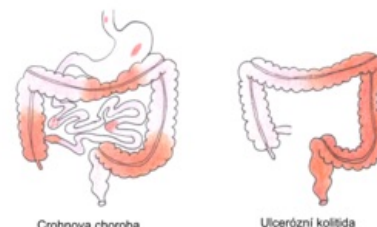
Among the **nonspecific intestinal inflammations**<sup>[1]</sup> include Crohn's disease (*ileitis terminalis*) and ulcerative colitis (*proctocolitis idiopathica*). These are chronic inflammatory diseases of the digestive tract, which are often accompanied by abundant extraintestinal symptoms. Both diseases begin in childhood or during adolescence and their etiology is unclear. The incidence and prevalence of non-specific intestinal inflammation has been increasing in recent years, 20-30% of patients are children under the age of 18.<sup>[2]</sup>

## Crohn's disease

It is a chronic non-specific inflammation of the small or large intestine (or any part of the GIT). It is segmental or multisegmental, transmural, in typical cases granulomatous inflammation.

## Ulcerative colitis

Non-specific hemorrhagic-catarrhal or ulcerative inflammation of the anus and the adjacent part (or the entire colon) with an abrupt or chronically exacerbating course.



Crohn's disease vs. ulcerative colitis

## Indeterminate (undetermined) colitis

It is an inflammation of the large intestine with characteristic overlapping features of Crohn's disease and ulcerative colitis or with various atypical signs that make it impossible to clearly classify the disease.<sup>[2]</sup>

	Crohn's disease	ulcerative colitis <sup>[3][2]</sup>
localization	the entire digestive tract, most often the terminal ileum	rectum and colon
mode of disability	segmental (alternation of inflamed and unaffected sections)	continuous progress in the oral direction
Abdominal X-ray	thickening of the intestinal wall, stenosis	extinct haustration
endoscopy	discontinuous involvement, focal aphthae, linear ulcers	hemorrhagic mucosa, diffuse inflammation, pseudopolyps
histology	inflammation of all layers of the intestinal wall (transmural)	inflammation of the mucous membrane and submucosa
	typical epithelioid granulomas, lymphocytic infiltrates	cryptitis, crypt abscesses
clinical picture	abdominal pain, diarrhea - rarely with blood	bloody diarrhea with tenesmus
	fever, weight loss, anorexia, growth retardation	
complications	formation of fistulas, stenoses and abscesses	increased risk of cancer

 For more information see Crohn's Disease.

 For more information see Ulcerative colitis.

## Links

## Related Articles

- Autoimmune diseases • Diarrheal diseases (signpost) • Pseudomembranous enterocolitis

## External links

- ZÁDOROVÁ, Zdena. *Czech Gastroenterological Society : Nonspecific intestinal inflammation* [online]. ©2007. [cit. 2010-05-02]. <<https://www.cgs-cls.cz/informace-pro-pacienty/nespecificke-strevni-zanety/>>.

## References

- ŠERCLOVÁ, Z. *Recommended procedures for surgical treatment of patients with non-specific intestinal inflammation - Part 1: preoperative preparation* [online]. ©2015. [cit. 2019-06-07]. <<https://www.cgs-cls.cz/wp-content/uploads/2017/02/06.pdf>>.
- LEBL, J - JANDA, J - POHUNEK, P. *Clinical Pediatrics*. 1. edition. Galen, 2012. 698 pp. pp. 311-318. ISBN 978-80-7262-772-1.
- MUNTAU, . *Pediatrics*. 4. edition. Grada, 2009. pp. 372- 377. ISBN 978-80-247-2525-3.