

# Musculus tibialis anterior

The tibialis anterior muscle descends in front of the inner ankle under the retinaculum musculorum extensorum to the inner edge of the leg, from there it continues under the plantar.

**Origin:** outer edge of the tibiae, membrana interossea cruris.

**Attachment:** medial cuneiform bone, bases palcového metatarsu.

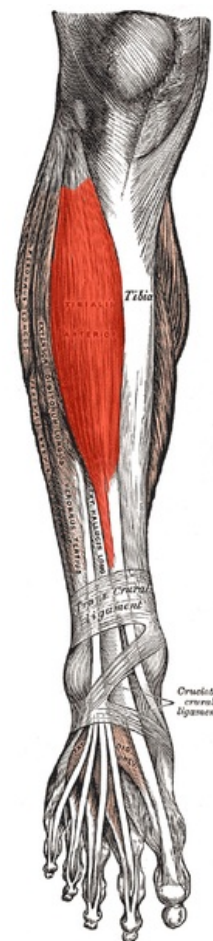
**Innervation:** n. fibularis profundus ( $L_4-S_1$ ).

**Function:** supination, dorsiflexion of the foot (holds the transverse arch of the foot).

## Links

## References

- ČIHÁK, Radomír. *Anatomie 1*. 2. edition. Grada, 2001. 497 pp. ISBN 80-7169-970-5.
- VIGUÉ, Jordi. *Atlas lidského těla*. 3. edition. Rebo, 2007. ISBN 978-80-7234-881-7.



**Tibialis anterior muscle**