

Musculus rectus abdominis

Origin:

- 5.-7. ribs;
- xiphoid process.

Insertion: pubic bone between symphysis and tuberculum pubicum.

Innervation:

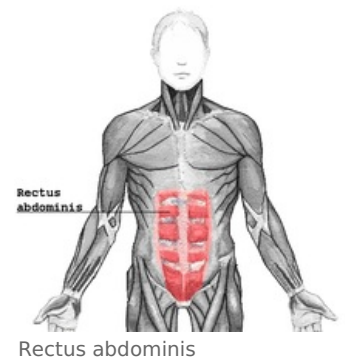
- nervus intercostalis (7.-11.);
- nervus subcostalis.

Function:

- bends the spine (ventral flexion)
- changes the tilt of the pelvis,
- participates in the abdominal press;
- accessory expiratory muscle.

Formations on the rectus abdominis muscle:

- tendinous intersection: three transverse tendinous bands crossing the muscle;
- rectus sheath: tendon sheath surrounding the muscle
- linea alba: fibrous band in the middle (vertically) of the muscle.



Links

References

- ČIHÁK, Radomír. *Anatomie 1*. 2. edition. Grada, 2001. 497 pp. ISBN 80-7169-970-5.