

Musculus quadratus femoris

Origin: outer edge of tuber ischiadicum.

Insertion: crista intertrochanterica of the femur.

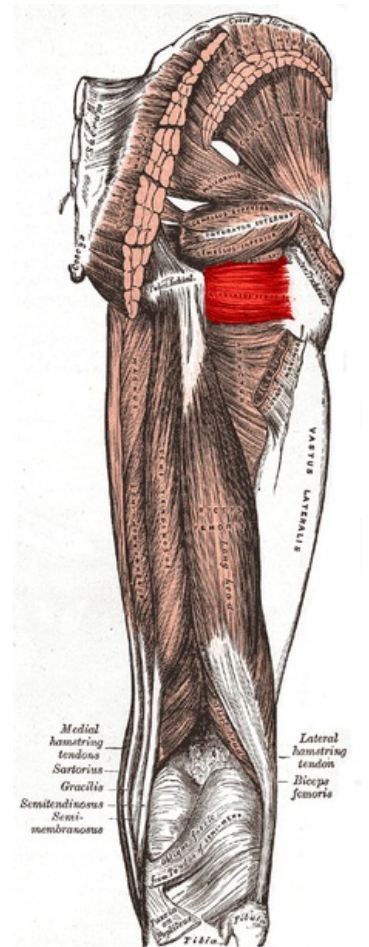
Inervation: plexus sacralis (L₄-S₁₋₂).

Function: external rotation in the hip joint .

Links

References

- ČIHÁK, Radomír. *Anatomie 1*. 2. edition. Grada, 2001. 497 pp. ISBN 80-7169-970-5.
- VIGUÉ, Jordi. *Atlas lidského těla*. 3. edition. Rebo, 2007. ISBN 978-80-7234-881-7.



Quadratus femoris muscle