

Musculus coracobrachialis

Beginning: *processus coracoideus scapulae*.

Tendon: in continuation of *crista tuberculi minoris humeri*.

Innervation: *n. musculocutaneus* (C6 and C7).

Function: auxiliary adduction and auxiliary ventral flexion of the shoulder joint.

Blood supply: *a. circumflexa humeri cranialis*

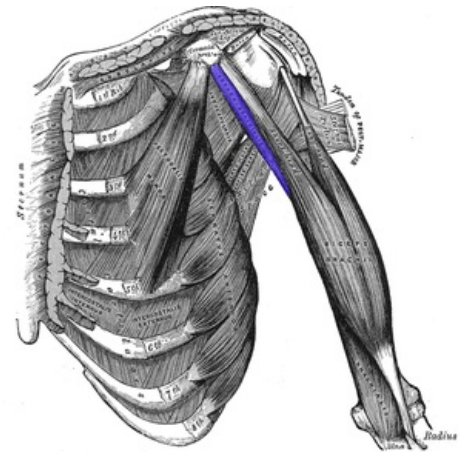


Image of the Coracobrachialis muscle.

References

- ČIHÁK, Radomír a Miloš GRIM. *Anatomie*. 2., uprav. a dopl vydání. Praha : Grada Publishing, 2002. 470 s. sv. 1. ISBN 80-7169-970-5.