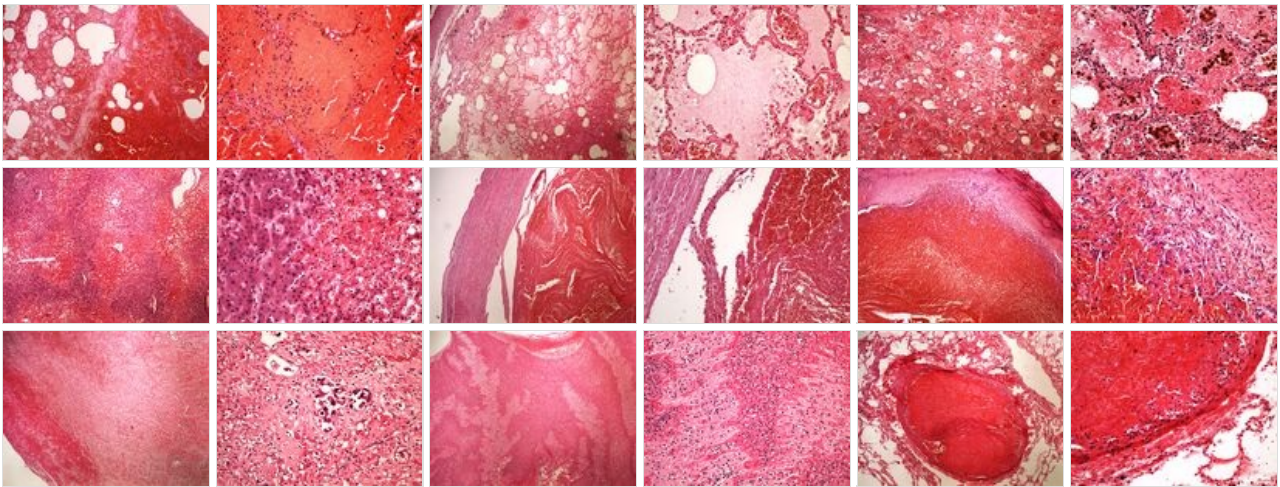
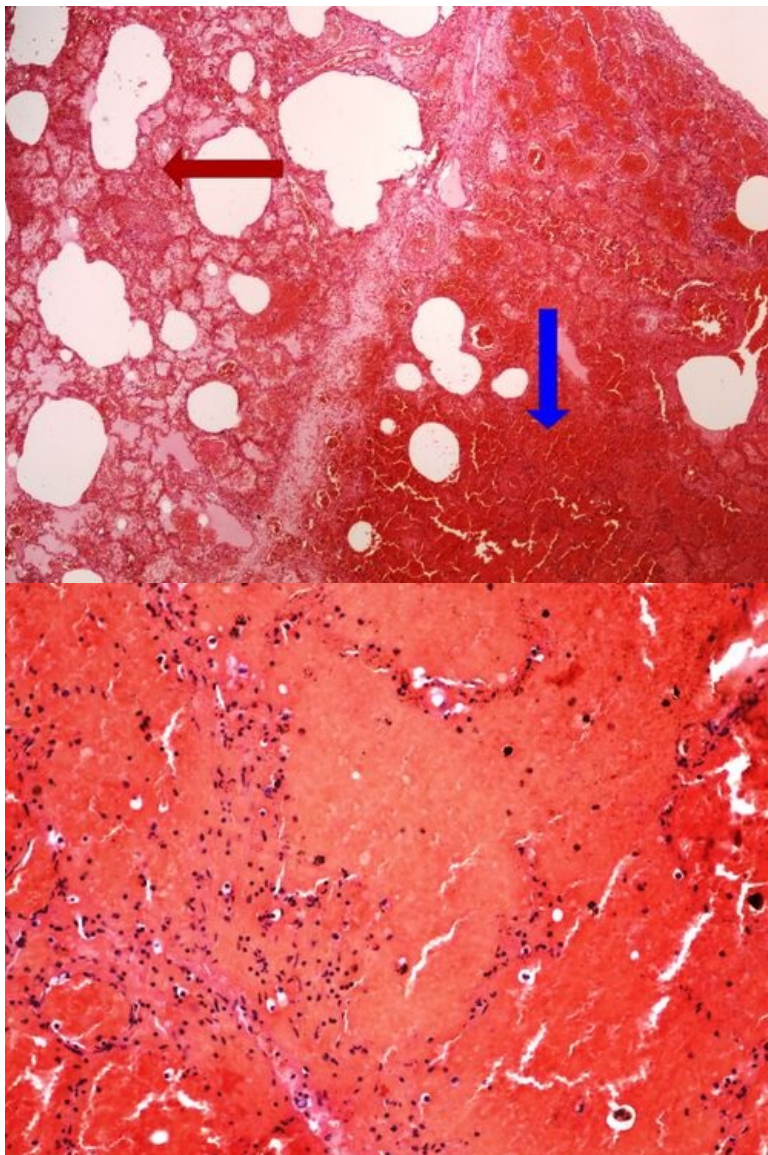


Module GFPP - Practice no. 5

Summary



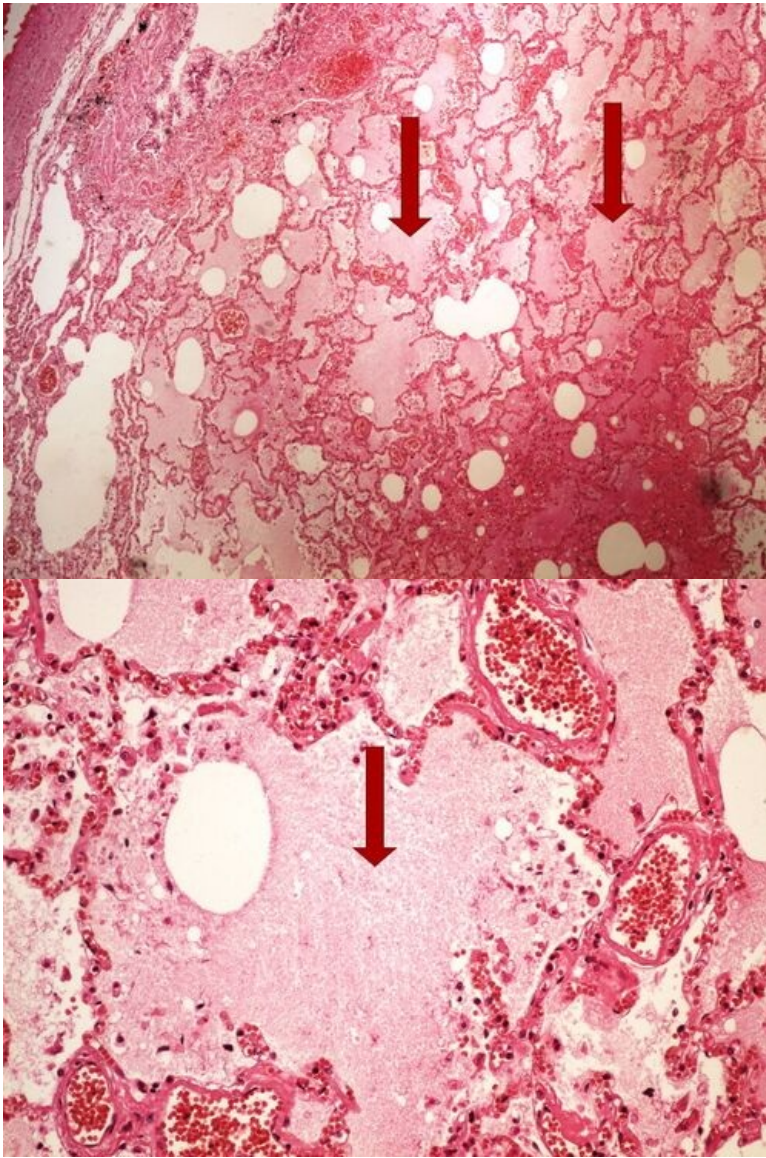
Slide no.1 and no.2 - hemorrhagic necrosis



Structures to know

[Expand]

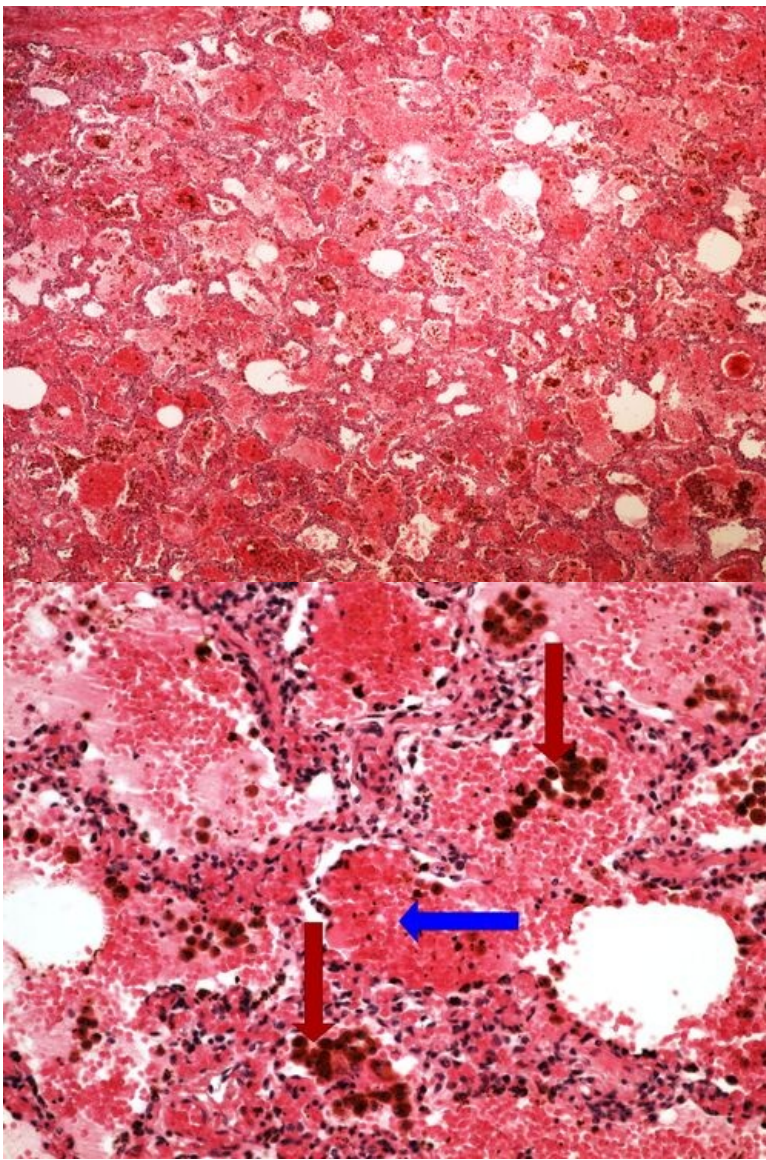
Slide no.3 and no.4 - pulmonary edema



Structures to know

[Expand]

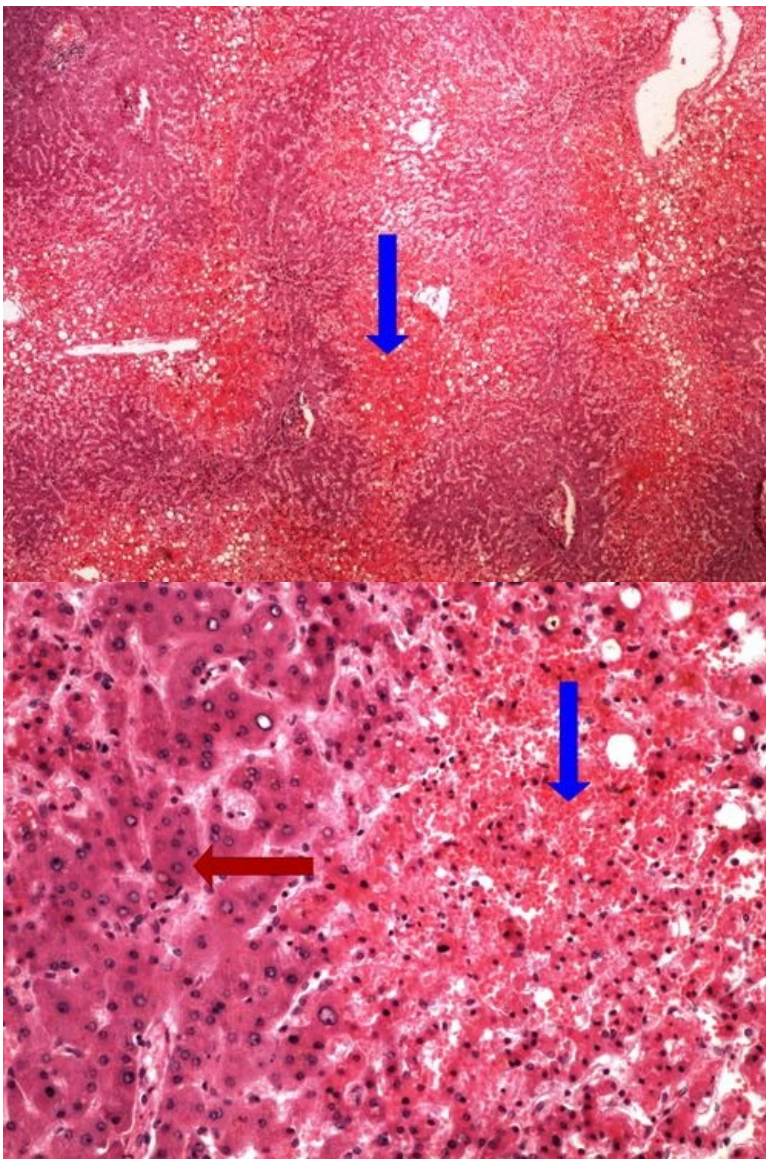
Slide no.5 and no.6 - rusty induration of the lungs



Structures to know

[\[Expand\]](#)

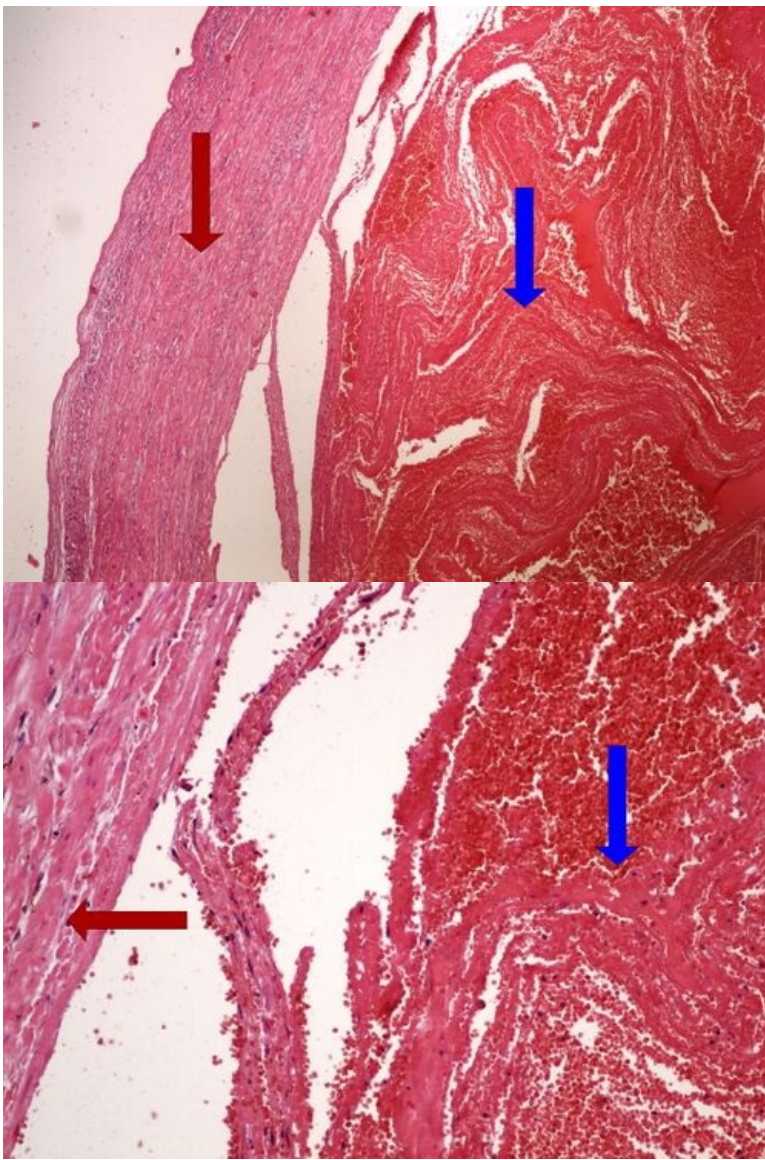
Slide no.7 and no.8 - chronic venostasis of the liver



Structures to know

[Expand]

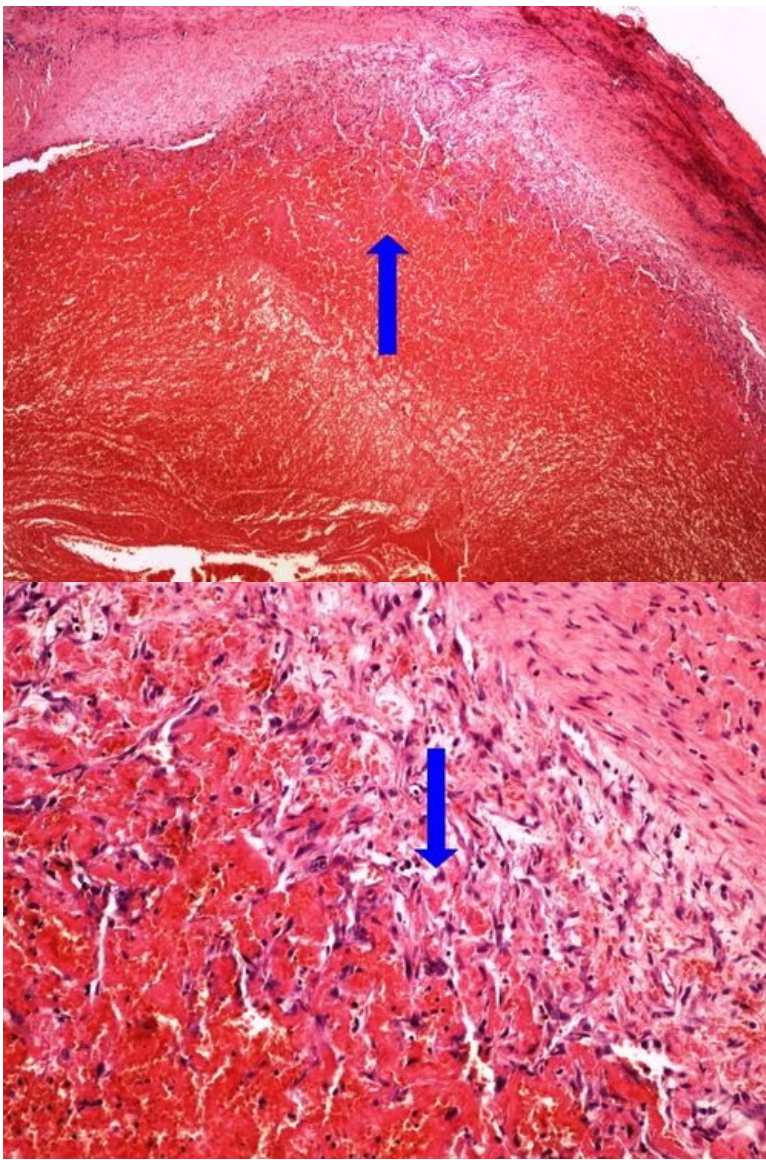
Slide no.9 and no.10 - fresh thrombosis



Structures to know

[Expand]

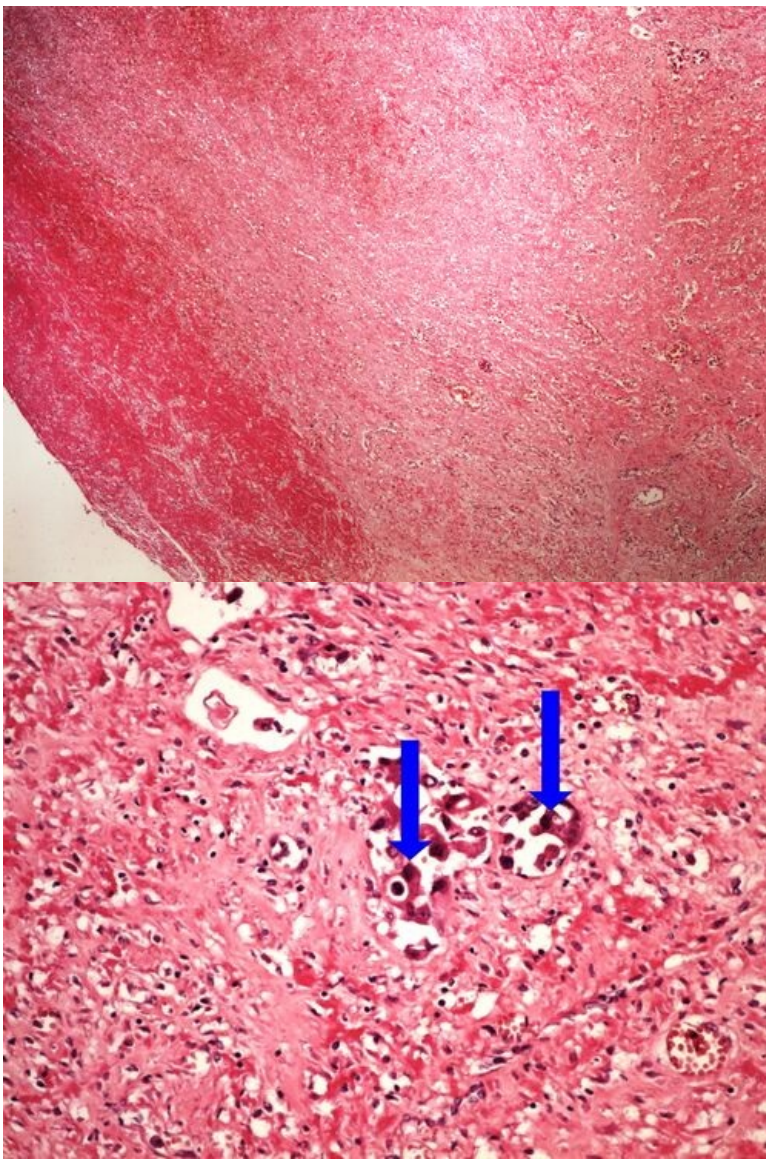
Slide no.11 and no.12 - organizing thrombosis



Structures to know

[\[Expand\]](#)

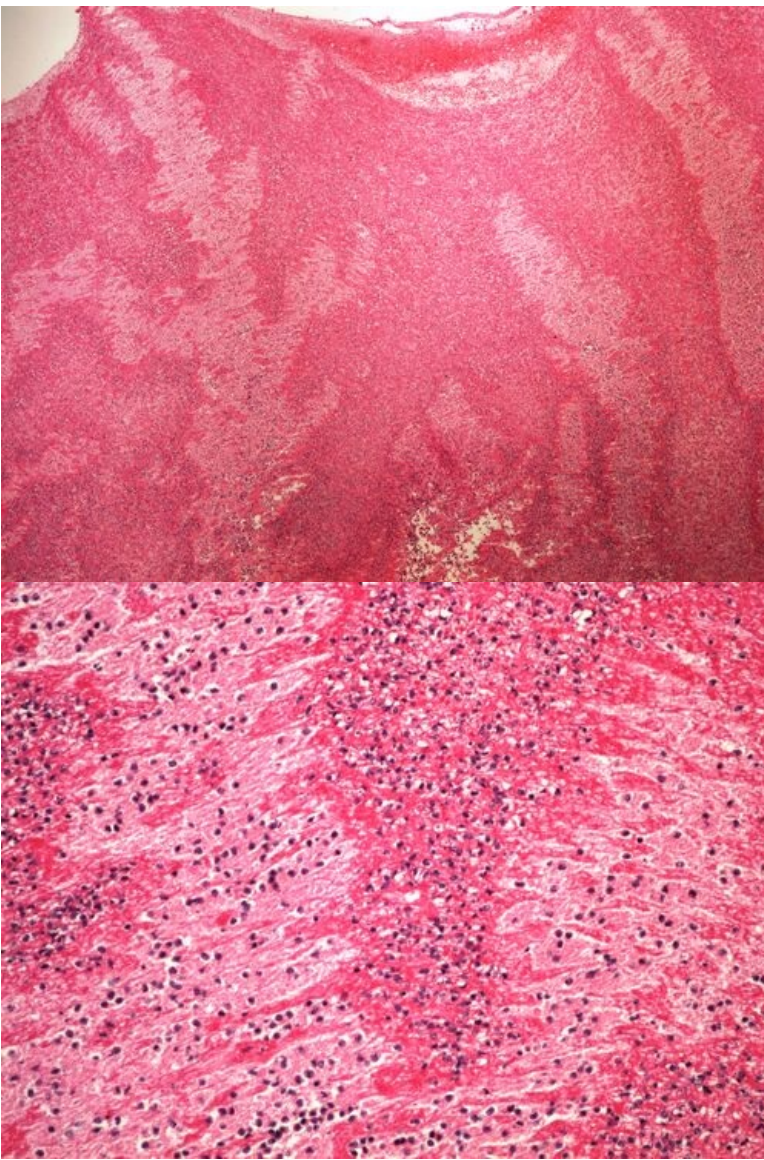
Slide no.13 and no.14 - tumor embolism



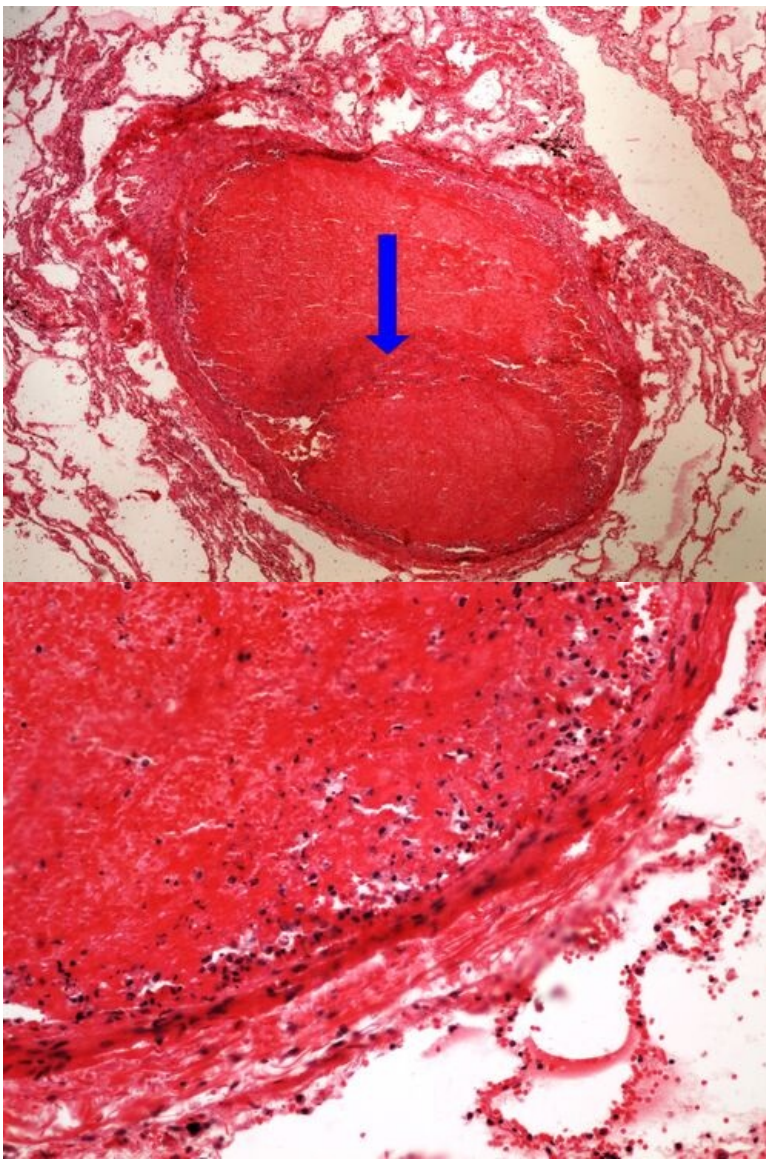
Structures to know

[\[Expand\]](#)

Slide no.15 and no.16 - mixed thrombus



Slide no.17 and no.18 - thrombotic embolism of the lung



Structures to know

[\[Expand\]](#)

Links

Navigation

[← Practice no. 4](#)

[Module GFPP \(3. LF UK\)](#)

[Practice no. 6 →](#)