

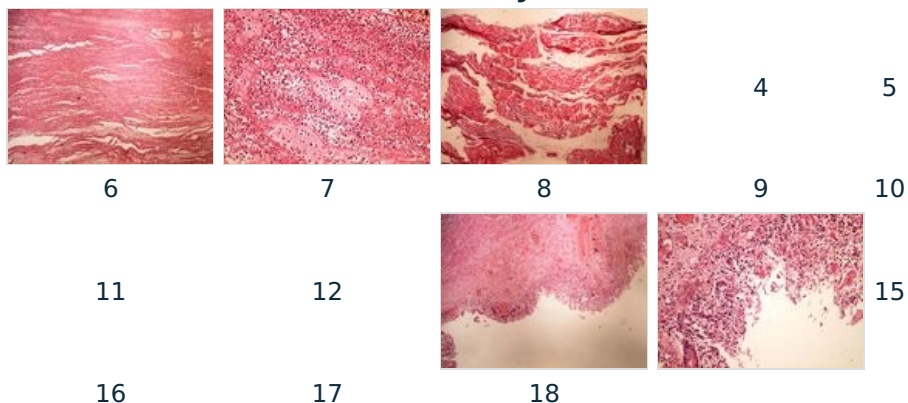
# Module GFPP - Practice no. 2

## Under construction / Forgotten

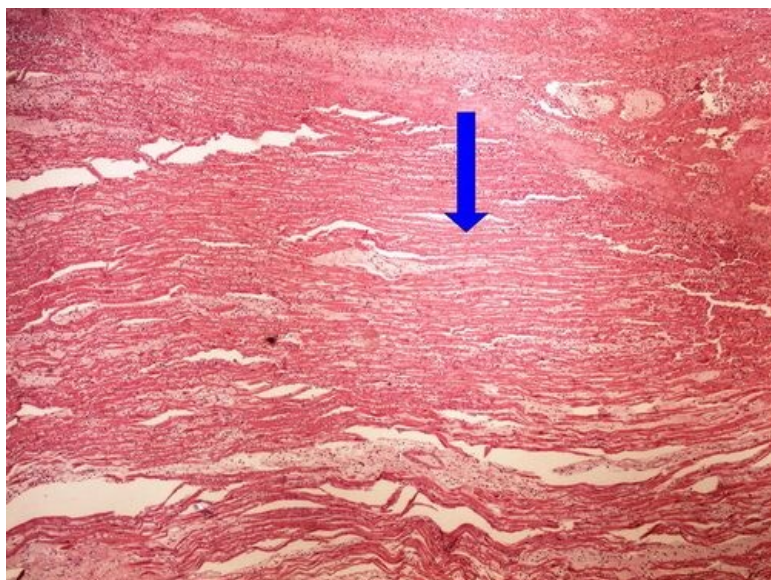
This article was marked by its author as *Under construction*, but the last edit is older than 30 days. If you want to edit this page, please try to contact its author first (you will find him in the history ([https://www.wikilectures.eu/index.php?title=Module\\_GFPP\\_-\\_Practice\\_no.\\_2&action=history](https://www.wikilectures.eu/index.php?title=Module_GFPP_-_Practice_no._2&action=history))). Watch the page as well. If the author will not continue in work, remove the template {{Under construction}} and the page.

Last update: Monday, 08 Dec 2014 at 5.29 pm.

### Summary



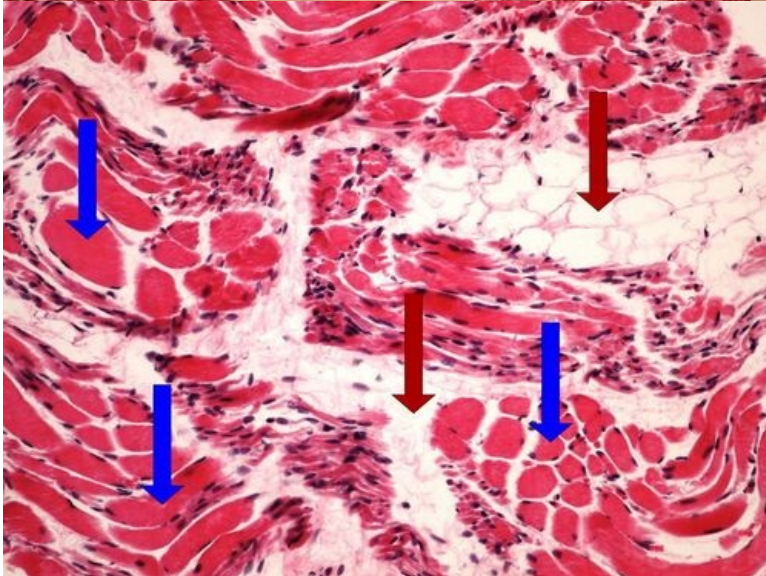
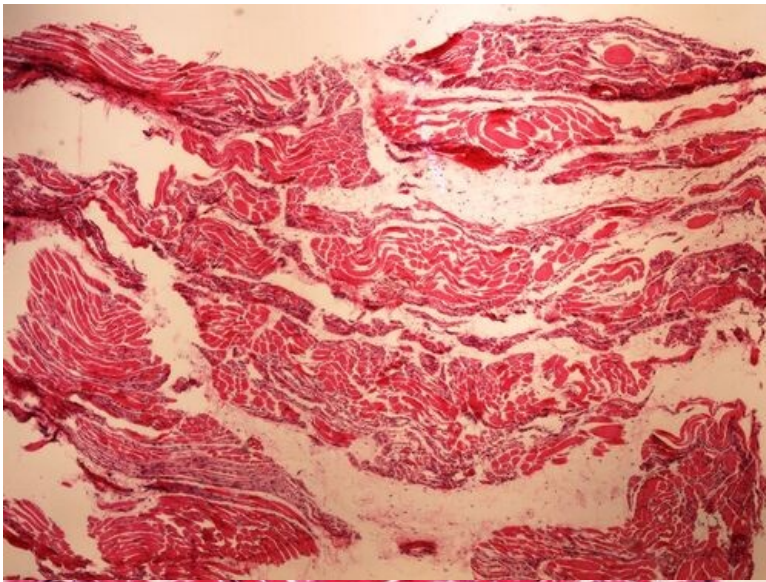
## Slide no.1 and no.2 - infarkt myokardu



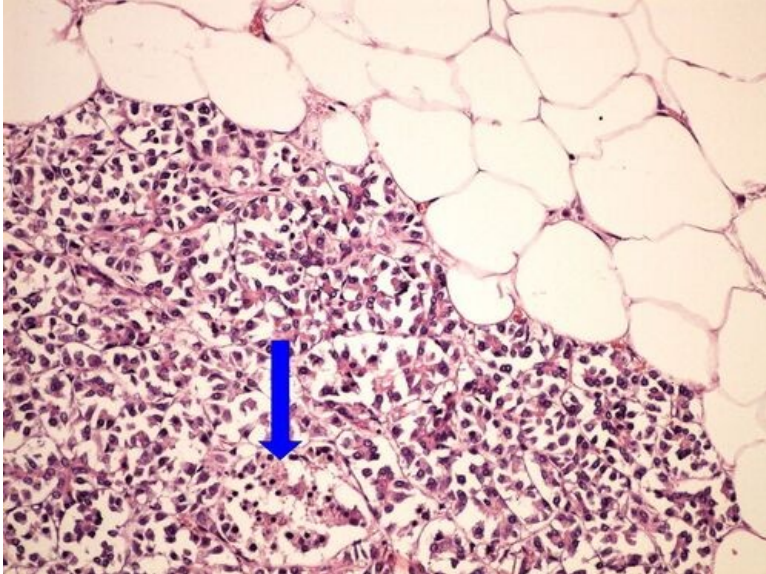
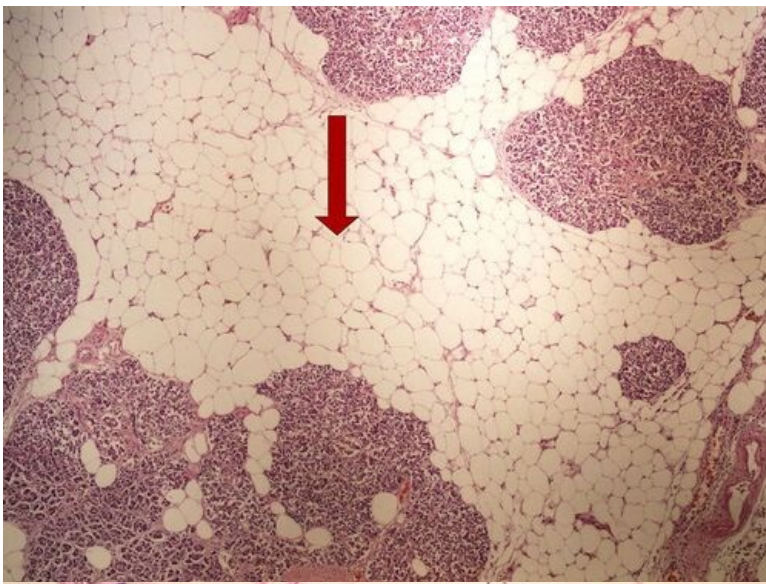
20x oznaceno.jpg

File:Z2-1infarction of myocardium infarkt myokardu

## Slide no.3 and no.4 - svalová atrofie [Expand]

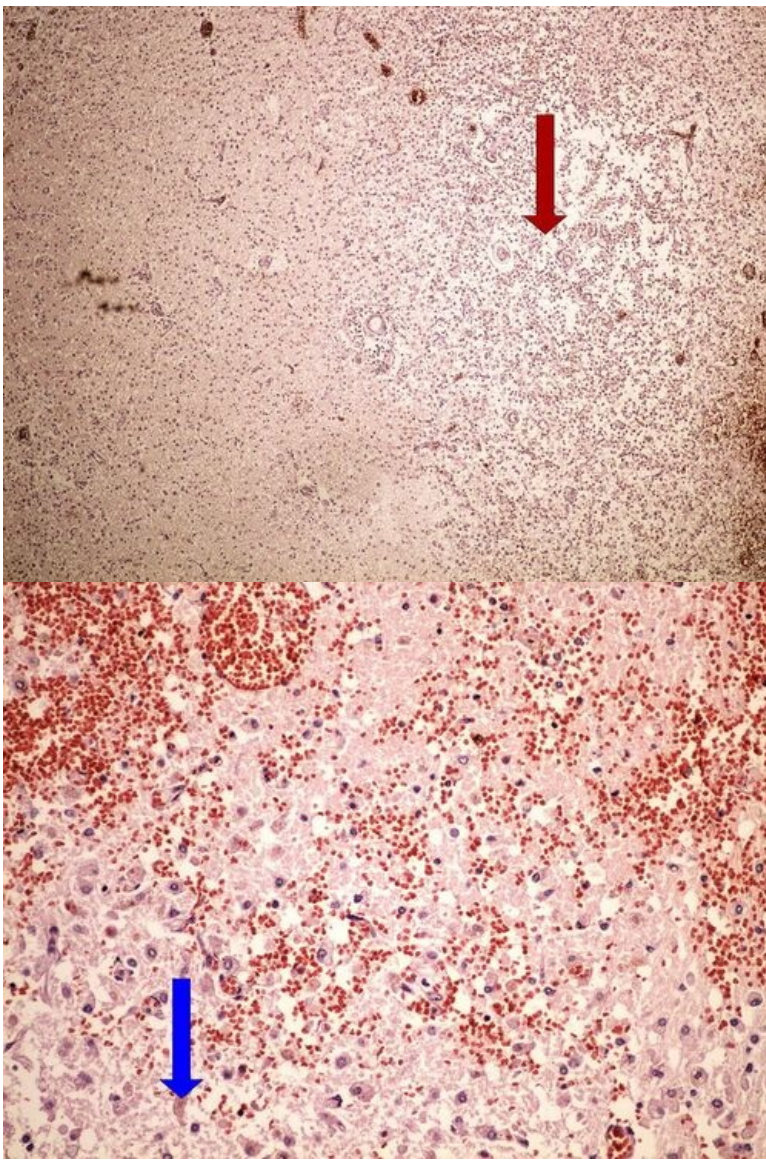


**Slide no.5 and no.6 - tuková atrofie pankreatu** [\[Expand\]](#)

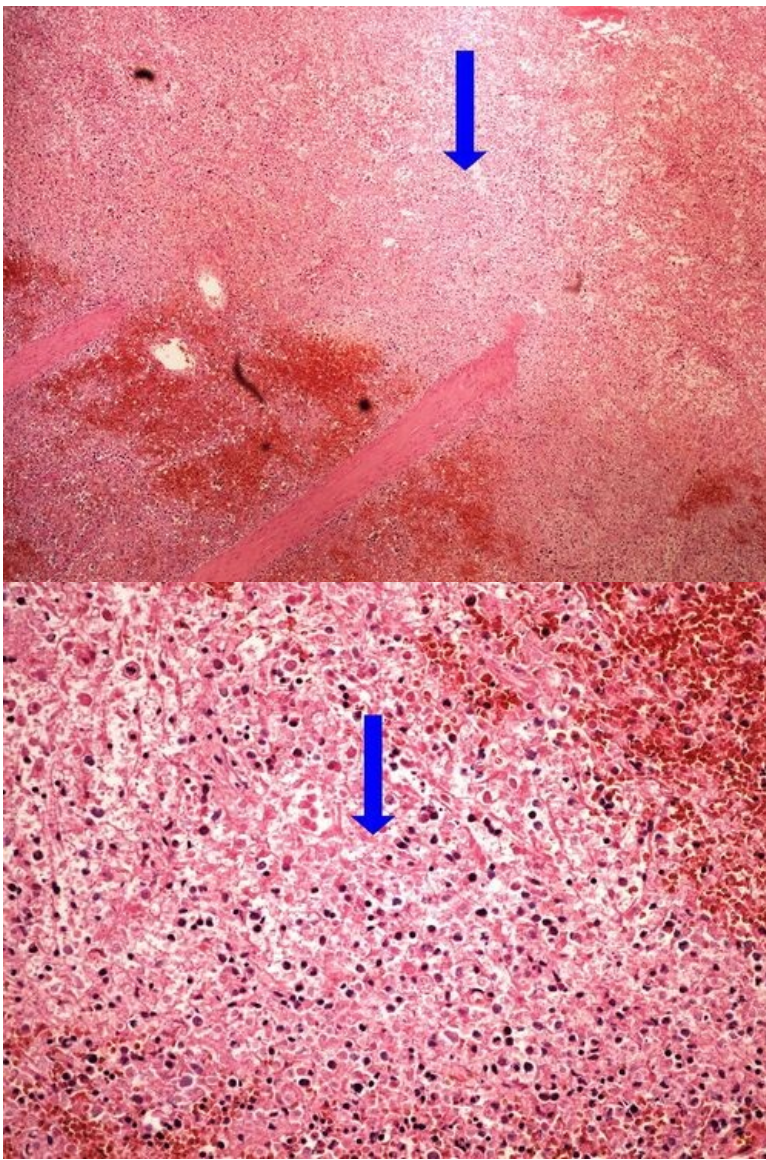


**Slide no.7 and no.8 -  
kolikvační necrosis**

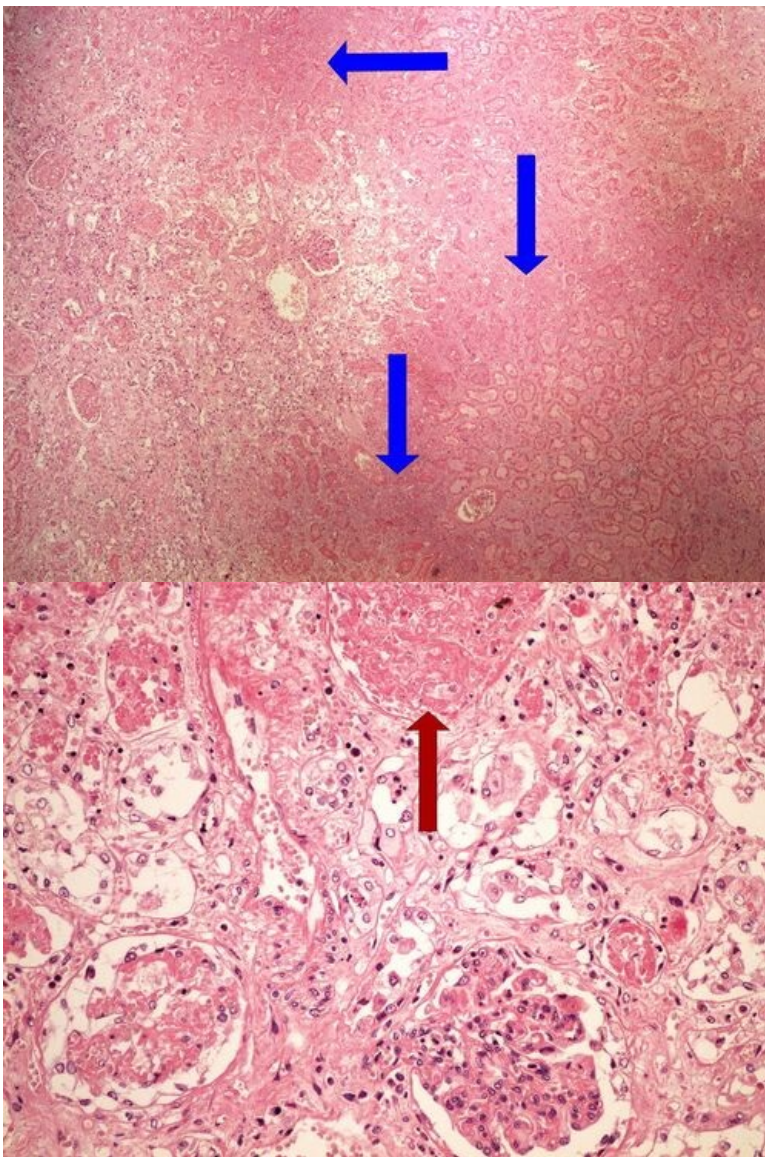
[Expand]



**Slide no.9 and no.10 - infarkt** [\[Expand\]](#)  
**sleziny**



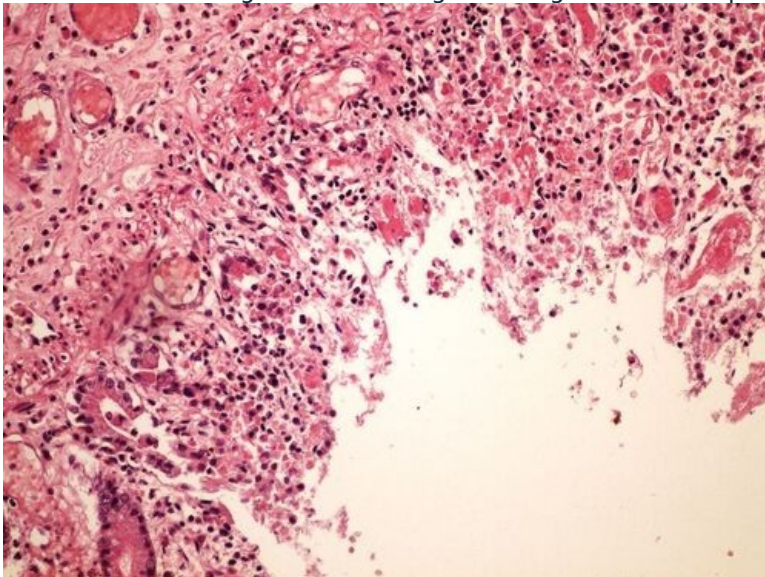
**Slide no.11 and no.12 - infarkt** <sup>[Expand]</sup>  
**ledviny**



**Slide no.13 and no.14 -  
hemoragická infarzace střeva**

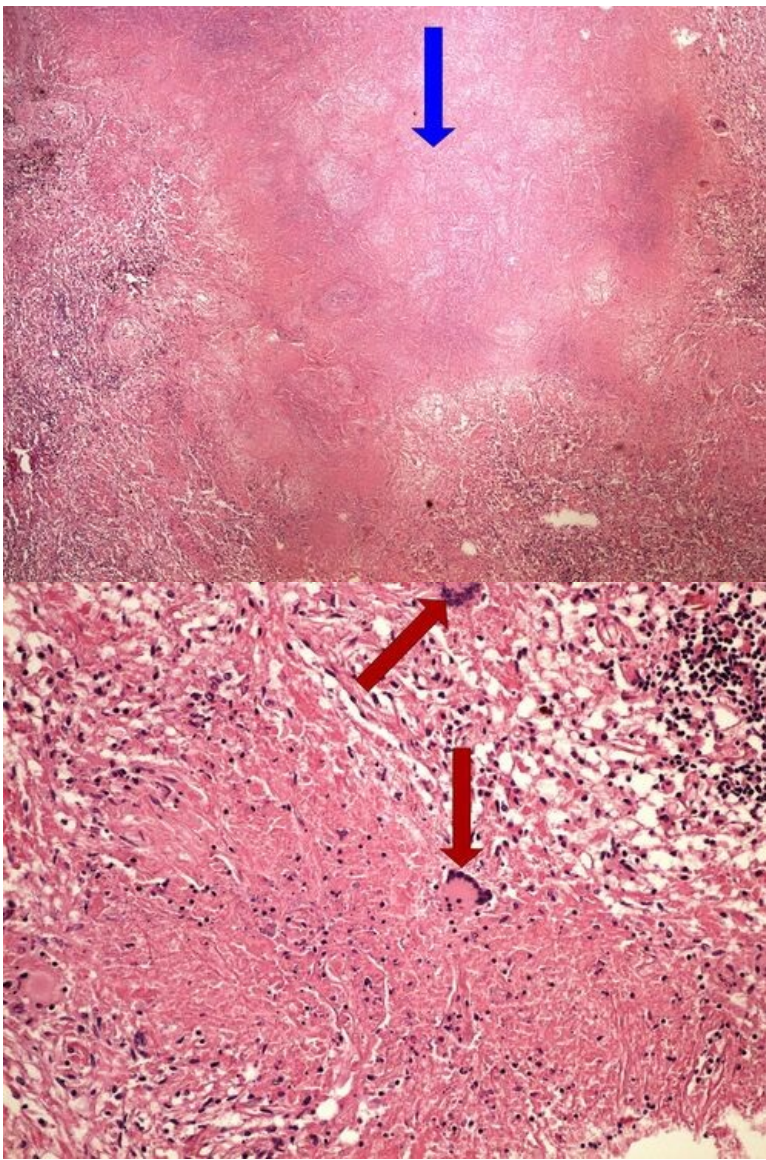
[Expand]

File:Z2-5 hemorrhagic necrosis lung hemoragicka nekroza plíce 4x oznaceno.jpg

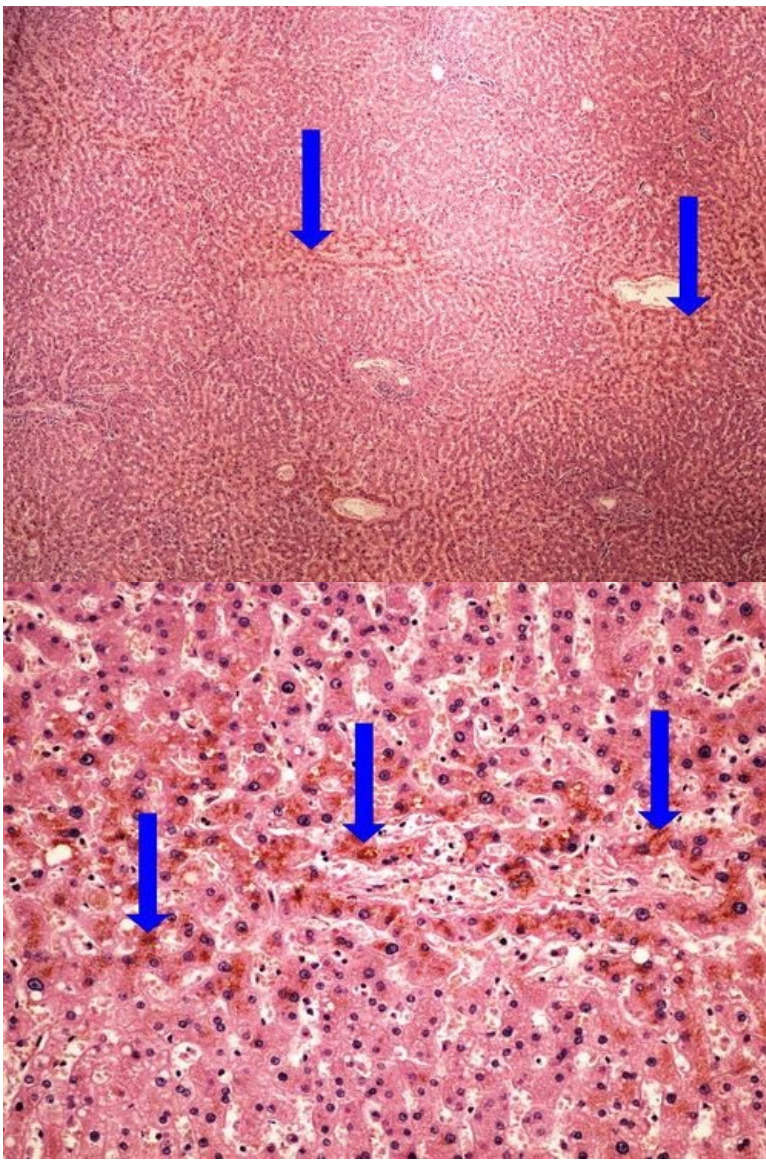


**Slide no.15 and no.16 -  
kaseózní necrosis plic**

[Expand]



**Slide no.17 and no.18 - hnědá** [\[Expand\]](#)  
**atrofie jater**



**Odkazy**

[\[Expand\]](#)

**Navigace**

[← Practice no. 1](#)

[Module GFPP \(3. LF UK\)](#)

[Practice no. 3 →](#)