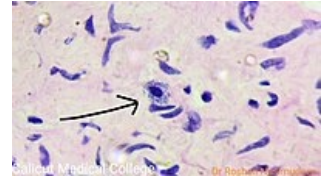


# Mast cells

**Mast cells** (or mast cells or heparinocytes) are mainly located in connective tissue or along blood capillaries. They are similar to basophilic granulocytes – they have granules with heparin (hence heparinocytes) and histamine in their cytoplasm and receptors for IgE on their surface. They are used in allergic reactions and inflammatory processes.




Mast cell under the microscope

## Links

## Source

- ŠVÍGLEROVÁ, Jitka. *Žírné buňky* [online]. [cit. 2010-11-9]. <[https://web.archive.org/web/20160306065550/http://wiki.lfp-studium.cz/index.php/Žírné\\_buňky](https://web.archive.org/web/20160306065550/http://wiki.lfp-studium.cz/index.php/Žírné_buňky)>.



Mast cell