

Ménière's disease

Ménière's disease is a disease **of the inner ear** arising from **dysfunction of the endolymphatic sac**. Women and men are affected equally. The disease occurs mainly in patients aged 30–60 years.

Pathogenesis

Saccus endolymphaticus ensures the resorption of endolymph. Its dysfunction results in the accumulation of endolymph and expansion of the labyrinth, leading to its rupture. Endolymph is rich in potassium and therefore diffuses into the potassium-poor perilymphatic fluid. This leads to depolarization of the *vestibulocochlearis* neuron.

Clinical signs

The main symptoms of Ménière's disease include:

- **Paroxysmal** vertigo – these are bouts of rotational vertigo, often preceded by an aura.
- Tinnitus – typically unilateral.
- Hypacusis – typically one-sided perceptual.

There are also frequent feelings of pressure in the ear, nausea and vomiting.

Diagnostics

Ménière's disease can be diagnosed based on:

- **anamnesis** (two or more past vertigo attacks);
- **audiometry** (we demonstrate a shift in hearing threshold by more than 10 dB at two different frequencies);
- **exclusion** of other pathological conditions that could lead to a similar clinical manifestation (indicated methods may include e.g. CT, MRI, lumbar puncture, angiography...).

Treatment

The causal treatment for Ménière's disease is **unknown**. They are used:

- special **dietary measures** – limit salt, limit intake of caffeine, alcohol;
- **diuretics**;
- **betahistín**.

In case of failure of conservative therapy, surgery can be performed (on the saccus endolymphaticus).

Links

Related Articles

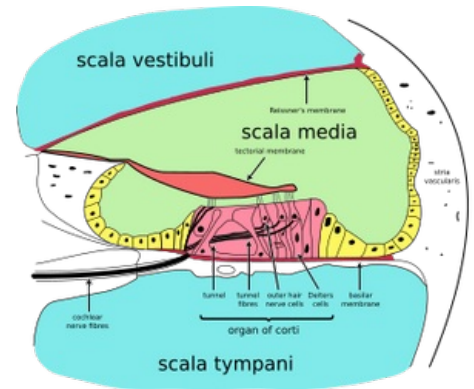
- Meniere's disease/PGS/diagnosis

Source

- BENEŠ, Jiří. *Studijní materiály* [online]. ©2007. [cit. 2009]. <http://jirben2.chytrak.cz/materialy/orl_jb.doc>.

References

- KLOZAR, Jan, et al. *Speciální otorinolaryngologie*. 1. edition. Praha : Galén, 2005. 224 pp. ISBN 80-7262-346-X.
- MLČOCH, Zbyněk. *Menierova nemoc, Menierův syndrom – příznaky, projevy, léčba, diagnostika, vyšetření* [online]. ©c2003-2010. [cit. 2017-10-12]. <<http://www.zbynekmlcoch.cz/informace/medicina/nemoci-lecba/menierova-nemoc-menieruv-syndrom-priznaky-projevy-lecba-diagnostika-vysetreni>>.
- Vertigo Academy. *Endolymfatický hydrops : Ménièreova choroba a Ménièreův syndrom* [online]. [cit. 2010-05-20]. <<http://www.vertigoacademy.cz/zavrat/priciny>>.



Transverse section of the cochlea : the scala media is filled with endolymph, the scala vestibuli and scala tympani are filled with perilymph