

# Lower jaw

The **lower jaw** (mandible) is an unpaired bone belonging to the facial part of the skull. The mandible is made up of a **body (corpus mandibulae)** and **two arms (rami mandibulae)**. Each of the arms makes an angle of approximately 120-125° with the body of the jaw in an adult.

## Corpus mandibulae

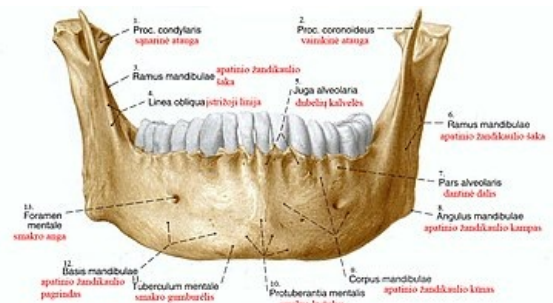
The *body* of the mandible is parabolically curved and its shape varies slightly from person to person. It is composed of two halves, which in the middle plane are formed by a fusion, formed in the first year of life.

- The *lower edge* of the bone is called the **basis mandibulae** and forms the basis of the lower outline of the face.
- The outer front surface of the mandible is significantly arched and forms a chin protuberance (protuberantia mentalis). Externally from the chin, on both sides, there is a *tuberculum mentale*, which is conditioned by the individual shape of the individuals chin. Laterocranially from there we find the **chin opening (foramen mentale)** into which the mandibular canal (canalis mandibulae) opens.

The mental foramen is not a very prominent opening, but the fact that it is located near the root of the second molar can help us in finding it.

- Across the **external lateral surface** runs the **linea obliqua** - a ridge passing in the region of the shoulder of the bone into the **processus coronoideus** (see below).
- **Pars alveolaris** is located on the upper edge of the body. As with the maxilla, it is arranged in the shape of a kind of tooth attachment made up of tooth beds (alveoli) in which the teeth are anchored. The individual the alveoli are separated from each other by septa (septa interalveolaria). In teeth with multiple roots, the alveoli are further divided by partitions between the roots (septa interradicularia).

The appearance of the *pars alveolaris* is dependent on the presence of teeth. After the loss of the denticles, the bone mass of the alveoli gradually breaks down and the body of the mandible decreases.



Mandibula - front view

- The inner surface bears a spine called *spina mentalis* at its center, which is the starting point of the muscles. In close proximity to the *spina mentalis*, there is a caudally paired pit - *fossa digastrica*. Lateral from the imaginary midline, we find another relatively prominent depression - *fovea sublingualis*, which is the imprint of the sublingual salivary gland. Sometimes we can also distinguish a laterodorsally lying imprint of the submandibular salivary gland called *fovea submandibularis*. Another significant formation on the inner surface of the body is a longitudinal groove called *linea mylohyoidea*. It starts with *m. mylohyoideus*. *Tuberositas pterygoidea* is a roughness in the place of the *angulus mandibulae*. It is attached to it by the *m. pterygoideus medialis*.

## Summary of significant formations on the body of the mandible

1. protuberantia mentalis
2. tuberculum mentale
3. mental foramen
4. canalis mandibulae
5. linea obliqua
6. dental alveoli
7. spina mentalis
8. fossa digastric
9. fovea sublingualis
10. fovea submandibularis
11. mylohyoid line
12. pterygoid tuberosity

## Ramus mandibulae

The body of the mandible extends on the sides in paired **rami mandibulae**. Both are finished with prominent protrusions. The posterior and larger of the projections is the articular **processus condylaris** ending in the *caput mandibulae* and a smaller, more ventrally placed projection - the **processus coronoideus**, on which tightens the massive *temporalis muscle*.

 For more information see *Articulatio temporomandibularis*.

- The most prominent opening on the shoulder of the mandible is the **foramen mandibulae**, located in the middle of its inner surface. It is the entrance to the mandibular canal.
- ***Tuberositas masseterica*** is a roughness on the outside of the angulus mandibulae. It is attached to it by the m. masseter.
- ***Canalis mandibulae*** - the mandibular canal leads through the entire mandible and opens into the **foramen mentale** (see above). The n. alveolaris inferior runs through the channel (innervates the teeth) and along with it the corresponding artery and vein. It takes place close to the tips of the roots of the third molars, moving away from the roots towards the front. The distance of the canal from the root tips is individual - from a distance of a few mm to the close contact of nerves and vessels with the roots of the tooth. This is especially true for impacted lower wisdom teeth. During surgical extraction of the lower wisdom tooth, damage to this nerve can sometimes occur and subsequent loss of sensation in the lower lip area. Early removal of teeth that do not yet have fully developed roots significantly reduces this risk.

## Links

## References

- ČIHÁK, Radomír. *Anatomy 1*. 2. edition. Grada, 2001. 516 pp. ISBN 978-80-7169-970-5.
- SINĚLNIKOV, Rafail Davidovič. *Atlas of Human Anatomy*. 3. edition. Avicenum, 1980. 467 pp. vol. 1. The science of bones, joints, ligaments and muscles.