

Inguinal canal

The **inguinal canal**, or **canalis inguinalis**, is a 4–5 cm slit in the lower part of the abdominal wall. It lies above *the league. inguinale* in places where the bundles of the *obliquus internus abdominis* and *transversus abdominis* muscles no longer reach. Here, the abdominal wall is formed only by the aponeurosis of the *obliqui externi abdominis* muscle, the transverse fascia and the parietal peritoneum.

Contents of the inguinal canal

In men, it passes through *the canalis inguinalis funiculus spermaticus* (during intrauterine development, the testicles descend through the canal to the scrotum together with the peritoneal cavity - *proc. vaginalis peritoneae*), in women, *lig. teres uteri*. In both sexes, the *ilioinguinalis* nerve (ventral from the funiculus or ligament - often pierces the aponeurosis of the oblique muscle outside *the anulus inguinalis superficialis*) and the *genitalis n. genitofemoralis* (dorsomedially from the funiculus or ligament) also pass through here.

The inguinal canal begins deep in *the anulus inguinalis profundus*, then runs above *the lig. inguinale Pouparti* obliquely mediocaudally and into the subcutaneous opening in *the anulus inguinalis superficialis*.

Anulus inguinalis superficialis (subcutaneus)

It is an opening in *the aponeurosis muscoli obliqui externi abdominis* (it projects onto the inner surface of the abdominal wall into *the fossa inguinalis medialis*).

Boundaries

- **Craniomedially** : *crus mediale* – attaches to *the tuberculum pubicum* (continues to the other side as *lig. inguinale reflexum Collesi*);
- **caudolaterally** : *crus laterale* – merges with *the lig. inguinale*;
- **laterally** : *fibrae intercrurales* – run arcuately from *the ligaments. inguinale* perpendicular to both crura;
- **medially** : *lig. inguinale reflexum* – attaches to *the linea alba*, or is a continuation of the bilateral *crus mediale*.

Anulus inguinalis profundus (praeperitonealis)

It is not a true opening - it is the place where *the fascia transversalis* is funneled into the inguinal canal and continues as *the fascia spermatica interna*.

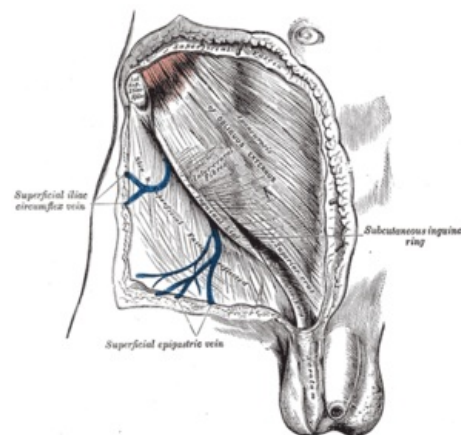
Boundaries

- **Cranially** : the lower edge of *the transversus abdominis* muscle;
- **caudally** : *lig. inguinale*;
- **medially** : *lig. interfoveolare* (strengthening of the transverse fascia given by the pull of *the ductus deferens*, which wraps around *the lig. interfoveolare*), *vasa epigastrica inferiora* (branches of *the a. iliaca externa*) run behind it;
- **laterally** : the angle where the bundles of *the transversus abdominis* muscle start from *the lig. inguinale*.

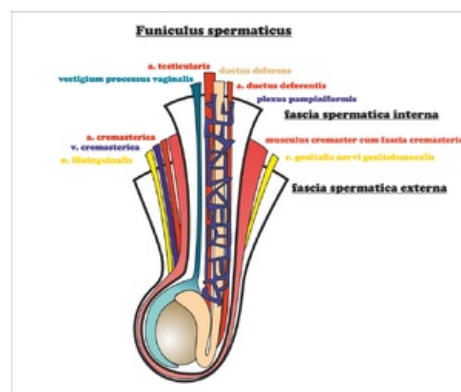
Walls of the inguinal canal

- **Ventrally** : *aponeurosis muscoli obliqui externi abdominis*;
- **dorsally** : *fascia transversalis* (bridging the gap between the lower edge of *the obliquus internus + transversus abdominis* and *lig. inguinale*), is strengthened in *the lig. interfoveolare* and in *the falx inguinalis*;
- **cranially** : the caudal edges of *the obliquus internus* and *transversus abdominis* muscles and their fused tendons continuing into *the tendo conjunctivus*, which runs along the outer edge of the attachment of *the recti abdominis* muscle to *the pecten ossis pubis*;
- **caudally** : *lig. inguinale Pouparti*.

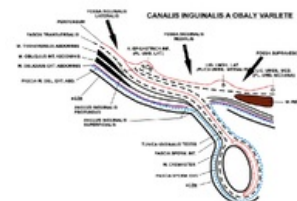
The section of the wall above the lig. inguinale



Superficial inguinal annulus.



Funiculus spermaticus



Canalis inguinalis and coverings of the testicle

It is formed only by the transverse fascia.

Division by the course of the leagues. interfoveolar to:

- **lateral** - *anulus inguinalis profundus* (in *the fossa inguinalis lateralis* , it is the inner gate of an indirect inguinal hernia - *hernia inguinalis indirecta*);
- **medial** - *trig. inguinale Hesselbachi* (in *the fossa inguinalis medialis* , is the inner gate of a direct inguinal hernia - *hernia inguinalis directa*).

Hesselbachi's trigonum inguinale is thus a weak spot of the abdominal wall bordered by thickened strips of transverse fascia (*lig. interfoveolare* , *falx inguinalis*) and *ligamentum inguinale* .

Links

Related articles

- Inguinal hernias
- Abdominal muscles
- Vas deferens

External links

- Mefanet - Tříselný kanál (<http://mefanet.lfp.cuni.cz/clanky.php?aid=5>)
- PAVLÍKOVÁ, Lada. *Tříselný kanál* [online]. Výukový portál Lékařské fakulty v Plzni [online], ©2009. The last revision 12.10.2011, [cit. 2011-11-27]. <<http://mefanet.lfp.cuni.cz/clanky.php?aid=5>>.

Source

- PASTOR, Jan. *Langenbeck' s medical web page* [online]. [cit. 2009]. <<https://langenbeck.webs.com/>>.