

Infectious Exanthematous Diseases in Childhood

Infectious exanthemas are infectious diseases with a characteristic **rash**. Exanthema is a sudden generalized eruption on the skin. Based on the nature of eruption, there are **maculopapular**, **vesicular**, and **hemorrhagic** rashes. Most infectious rashes of childhood are of viral origin, which resolve spontaneously within days or weeks without sequelae, and treatment is only symptomatic. Special attention should be paid to certain exanthematous infections during pregnancy that may compromise the development of fetus or cause an infection in the neonate.^[1]

Exanthematous diseases can be divided into classical exanthema and non-specific exanthema according to the pathogen and nature of the exanthema. Incidence of classical exanthema diseases are declining thanks to vaccination. On the contrary, there is an increase in diseases with uncharacteristic and inconstant exanthema with various infectious agents being involved.^[1]

Previously, the most common childhood exanthematous disease were named the first to sixth childhood diseases. This designation has survived to this day only in the fifth and sixth children's diseases.^[2]

Name of the Disease	Old Designation	Pathogen ^[2]	Incidence in ČR (2009) ^[3]	Vaccination
Measles	First childhood disease	<i>Morbillivirus</i>	5	mandatory(MMR)
Scarlet fever	Second childhood disease	<i>Streptococcus pyogenes</i>	3862	
Rubella	Third childhood disease	<i>Rubivirus</i>	6	mandatory (MMR)
Pseudoscarlatina	Fouth childhood disease			
Erythema infectiosum	Fifth childhood disease	Human papillomavirus B19		
Exanthema subitum	Sixth childhood disease	Human Herpes Viruses 6 & 7		

In addition, classic exanthematous diseases include:

- Chickenpox (varicella) and shingles
- Primary infection by HSV
- hand-foot-mouth disease

Diseases accompanied by rash can be also caused by:

Virus

- adenoviruses - rubeoliform rash (on the face, torso and limbs);
- Cytomegalovirus - erythema or papular rash (on the trunk, limbs and palms);
- coxsackie viruses, ECHO viruses - papules, vesicles, petechiae (face, torso);
- Epstein-Barr virus - rubeoli/morbiliform rash (torso, limbs, face);
- Hepatitis B virus - papules, urticaria (auricle, forehead), generalized form: Gianotti-Crosti syndrome;
- HIV - rubeoli/morbiliform rash(face, torso);
- Mumps (parotitis epidemica) - erythema, papules, vesicles, urticaria (face, torso, limbs);
- Poxviruses - molluscum contagiosum, erythema (anywhere);
- Influenza A, influenza B, parainfluenza, RSV, rhinoviruses - erythema, papules, rubeoliform rash (face, torso, limbs)

Bacteria

- Toxic shock syndrome, Arcanobacterium haemolyticum infection, yersinosis, mycoplasma and chlamydial infections, bacterial pneumonia, empyema, abscess pneumonia with septic rash, meningococemia, post-splenectomy sepsis (OPSI syndrome), bacterial endocarditis, lymphoma, borreliosis, tularemia, rickettsiosis...
- ^[2]

Diagnostics

- Epidemiological history (occurrence of infection in the area, season)
- Personal history (past exanthematous infections, vaccinations, allergic manifestations)
- Current disease (prodromal symptoms, place of rash, nature and distribution of rash, presence of systemic symptoms, fever, administration of medication before rash)
- Clinical manifestations
- Laboratory findings, serum antibody tests and direct identification of the agent^[1]

Differential Diagnostics

Maculopapular Rashes

- Scarlatiniform (up to 1 mm, scarlet fever pattern) - Scarlet fever and some Enterovirus diseases
- rubeoliform (ca. 1-3 mm, rubella pattern) - rubella and sixth disease, infectious mononucleosis, diseases

- caused by adenoviruses, enteroviruses, transmissible respiratory viruses and primary HIV infection;
- morbilliform (larger than 3 mm, measles pattern) - measles, adenoviral and enterovirus disease, infectious mononucleosis (toxoallergic rash after ampicillin administration), primary HIV infection and post-vaccination measles syndrome;
- large spotted - fifth disease.

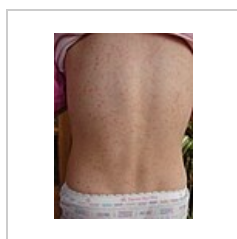
Vesicular Exanthemas

- Chickenpox, HSV-1, HSV-2 infections and some enterovirus diseases (e.g. EV 71 or *Coxsackie*), hand-foot-mouth disease.

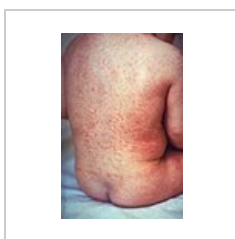
Hemorrhagic Exanthema

- Life-threatening bacterial infections (e.g. N. meningitidis, group B and C streptococci, S. pneumoniae and H. influenzae)
- Hemorrhagic fevers (Ebola, Lassa, Marburg disease, Congo-Crimea, Bolivian, Argentine, and hemorrhagic fevers with renal syndrome)^[2]

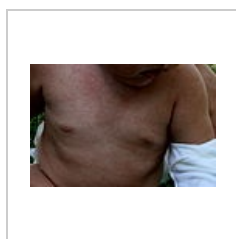
Images



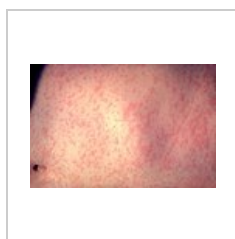
Scarlet fever exanthema




Rubella exanthema




Sixth child disease



Measles exanthema



Fifth child disease



measles vs. scarlet fever

Links

Related Articles

- Enterovirus exanthema

External Links

- Obrázkový atlas kožních chorob (<http://www.dermnet.com/>)
- Pediatrie pro praxi: Virové exantémy dětského věku (<http://www.pediatriepropraxi.cz/pdfs/ped/2008/06/03.pdf>)
- Pediatrie pro praxi: Infekční exantémová onemocnění v dětském věku (<http://www.pediatriepropraxi.cz/pdfs/ped/2009/03/09.pdf>)

Reference

1. KELBLEROVÁ, A. Infekční exantémová onemocnění v dětském věku. *Pediatrie pro praxi* [online]. 2009, roč. 10, s. 176, dostupné také z <<http://www.pediatriepropraxi.cz/pdfs/ped/2009/03/09.pdf>>. ISSN 1803-5264.
2. SEDLÁČEK, D - ŠTRUNCOVÁ, V. Virové exantémy dětského věku. *Pediatrie pro praxi* [online]. 2008, y. 9, p. 364, Available from <<http://www.pediatriepropraxi.cz/pdfs/ped/2008/06/03.pdf>>. ISSN 1803-5264.
3. STÁTNÍ ZDRAVOTNÍ ÚSTAV,, et al. *Vybrané infekční nemoci v ČR v letech 2000-2009* [online]. ©2010. [cit. 2010-08-15]. <<http://www.szu.cz/publikace/data/vybrane-infekcni-nemoci-v-cr-v-letech-1998-2007-absolutne>>.