

# Hypertension in pregnancy

**Hypertension in pregnancy** is defined as an increase in **systolic blood pressure  $\geq 140$  mmHg** and/or **diastolic pressure  $\geq 90$  mmHg**.<sup>[1]</sup>

The following types of hypertension can occur during pregnancy:<sup>[1]</sup>

- **Pre-existing hypertension**
- **Gestational hypertension** which appears after the 20th week of pregnancy. It is either accompanied by proteinuria (preeclampsia) or is without proteinuria.
- **Gestational hypertension together with preexisting hypertension**

**Late gestosis** is the name for a disease in the second half of pregnancy with edema, proteinuria and hypertension, occurring in 7-15 % of pregnancies. Since 1972, it has been divided into "preeclampsia" (moderate and severe), "eclampsia", "chronic (essential) hypertension", "chronic hypertension with superimposed preeclampsia" and "gestational hypertension". .

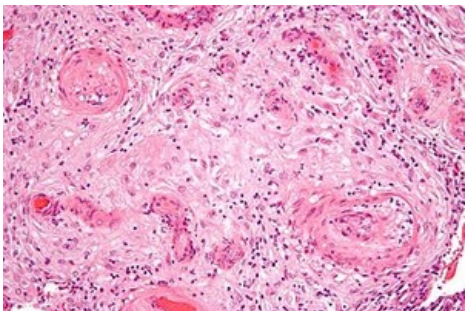
- Hypertension - if systole increases by 30 and diastole by 15 Torr above the norm before conception.
- Edema – total accumulation of fluid in all tissues, manifested as swelling of the face and limbs.
- Proteinuria – loss of more than 300 mg/day indicates preeclampsia.
  - causes – renal glomerular endotheliosis (hyaline and fatty degeneration of the glomerulus).

## Preeclampsia

*Synonyms:* **Pregnancy toxicosis, late gestosis, EPH gestosis (Edema, Proteinuria, Hypertension).**

The condition can result in a woman's life being threatened - eclampsia, it can be complicated by HELLP syndrome.

It occurs in 10-14% of primiparas, 5-7% of pluriparas. Risk factors for preeclampsia are primiparity, multiple pregnancy, low socio-economic status of the pregnant woman, occurrence of preeclampsia in the family, chronic renal diseases, hypertension, preeclampsia in a previous pregnancy, DM, hydatid mole, obesity and avitaminosis.

Preeclampsia	
	
Hypertrophic decidual vasculopathy in preeclampsia	
<b>Risk factors</b>	obesity, hypertension, DM, nulliparity <sup>[2]</sup>
<b>Classification and references</b>	
<b>ICD</b>	O10 – O14
<b>MeSH ID</b>	D011225
<b>OMIM</b>	189800
<b>MedlinePlus</b>	000898
<b>Medscape</b>	1476919

## Etiology

The etiology is unknown, with many theories. One of them is, for example, **abnormal trophoblastic invasion**, when the trophoblast does not grow into all capillaries. These vessels stiffen, have a high resistance (reminiscent of atherosclerosis), spasm occurs, which reduces blood flow through the placenta (IUGR and fetal hypoxia). This is followed by the development of hypovolemia and hypoperfusion of the uterine area, which is reflected in changes in blood flow through the mother's kidneys and liver. Another theory depends on **hemodynamic changes**. From

the fundus of the uterus (most preeclampsia occurs when the fetus is in the position of the fundus) blood flows mainly through the ovarian veins, which leads to blood stasis in the kidneys (the left ovarian vein opens directly into the renal vein), it is more pronounced in twins and polyhydramnios.

Other possibilities of occurrence depend on **immunological defects** (vasculitis), **genetic predisposition**, **dietary errors** (deficiency of proteins, thiamine, Fe, vitamins, excessive intake of salt, low calcium), **the action of oxygen radicals**, but also on **geographical factors**

## Pathogenesis

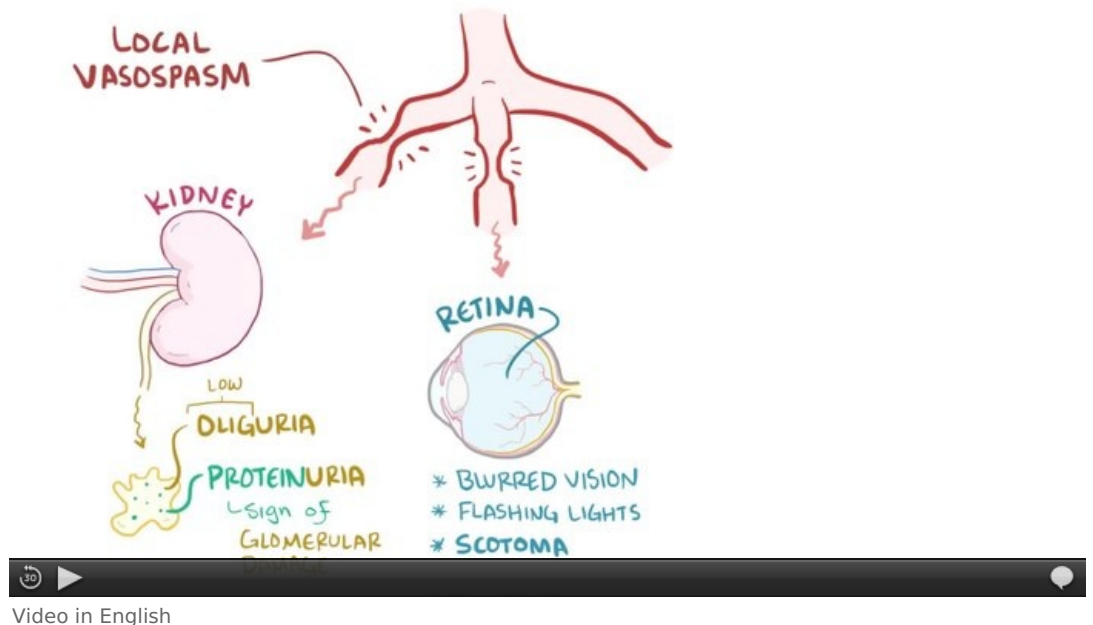
The main mechanism is **generalized vasoconstriction**, which causes the movement of water into the tissues and increases the hematocrit. The organism responds to this state of dehydration **hemodynamically** by redistributing the volume, which is caused by sympathetic activation. For this reason, the flow through the kidneys decreases, water and salts are retained and edema occurs. **Next, a humoral** reaction occurs, which includes the activation of the RAAS and changes in the action of prostaglandins, which change the balance between thromboxane and thus lead to preeclampsia. Prostacyclin also lowers blood pressure and prevents platelet aggregation, supports flow through the uterus (vasodilators), inhibits uterine contractions, thus reducing the incidence of preeclampsia. On the contrary, thromboxane acts as a vasoconstrictor, stimulates platelet aggregation and stimulates the activity of the uterus.

## Pathological changes in preeclampsia

The most important diagnostic triad: **Edema, proteinuria, hypertension**. The characteristic lesion is glomerular endotheliosis. The endothelium is swollen, amorphous, the capillary lumen is uneven. Its cause is vasospasm and ischemia. In moderate preeclampsia, glomerular flow decreases by 25%, in severe preeclampsia by 50%. The liver is affected by periportal hemorrhagic necrosis, thrombosis in arterioles and subcapsular hematomas. All these changes are related to generalized vasospasm and impaired coagulation. The most pathological changes are in the placenta (vascular changes on spiral arterioles, placental infarctions).

## Laboratory

**Proteinuria** is usually present in the laboratory. It is rated semi-quantitatively as + to +++, usually above 300 mg/day. Furthermore, uric acid, which is created due to an excess of oxygen radicals. Increasing ischemia increases the proportion of the xanthine oxidase enzyme, which also increases urate ( **a rise in urate above 320  $\mu\text{mol/l}$**  is a marker of preeclampsia). We also measure malondialdehyde (MDA) (a product of lipid peroxidation, a new marker).



Abnormal liver test values are increased when HELLP syndrome is suspected. There is often a rise in **hemoglobin and hematocrit**. We also evaluate changes in hemocoagulation (aPTT, fibrinogen, prothrombin time – usually normal), FDP rises, thrombin time increases.

## Care of women with preeclampsia

**We hospitalize** in the event of an increase in blood pressure above 140/90 or more (measured twice), or if there is an increase compared to the previous control by 30 (systole) or 15 (diastole). Furthermore, with proteinuria over 300 mg/day, rise in liver tests, evidence of thrombocytopenia and IUGR.

It is important to recognize the initial stages of preeclampsia (great weight gain (edema), headaches, visual disturbances, vomiting, pain in the epigastrium). The beginning is sometimes slow, sometimes fast. If all symptoms are not fully developed and there are no indications for hospitalization, we monitor patients on an outpatient basis.

In severe preeclampsia (BP above 160/110, proteinuria above 5 g/day, visual disturbances, initial stages of pulmonary edema), we consider termination of pregnancy.

## Treatment of impending eclampsia and eclamptic seizure

The main principles of therapy include timely treatment of hypertension, ensuring placental perfusion, prevention of spasms, fluid balance, reduction of edema. If it is a very severe, difficult to correct condition, we consider terminating the pregnancy.

Therapy includes strict bed rest, oxygenation with oxygen (oximeter monitoring). We administer magnesium sulfuricum, which promotes the release of prostacyclin from the endothelium, reduces vasoconstriction and platelet aggregation, and dilates CNS vessels (prevention of cerebral ischemia). We use calcium (chloratum or gluconicum) as an antidote. Symptoms of Mg overdose include a decrease in respiratory rate below 15 breaths/min and disappearance of the patellar reflex. Antihypertensives are given when diastole is above 95, the pressure is lowered slowly (there is a risk of fetal hypoxia). The drug of first choice is **methyldopa**, beta blockers (Vasokardin), calcium channel blockers can also be used (Cordipine). In acute conditions, we administer Dihydralazine-Nepresol (decrease in vascular resistance).

We supplement the treatment with infusion therapy (mannitol, frozen blood plasma, glucose 40%, etc.). Corticosteroids are administered in case of incipient brain edema.

## Lasting effects

There is emerging evidence of an increased risk of cardiovascular disease and kidney disease in women whose pregnancies have been complicated by preeclampsia. See: L. Greiffeneggová; D. Gross; P. Kaňová Pract. Medicine. 2017; 97(3): 117-122 online For physicians (registration required) (<https://www.prolekare.cz/specialist-agreement>)

## Links

### Related Articles

- HELLP syndrome
- Eclampsia
- Hypertension in pregnancy
- Hypertension
- Antihypertensives

### Literature

- BENEŠ, Jiří. *Studijní materiály* [online]. [cit. 2009]. <<http://jirben.wz.cz>>.

### References

1. WIDIMSKÝ JR., Jiří, et al. "Diagnostic and treatment procedures for arterial hypertension - version 2017. Recommendations of the Czech Society for Hypertension." Hypertension & cardiovascular prevention. Supplementum, 2018. Also available from WWW: <<http://www.hypertension.cz/sqlcache/widimsky-1-hypertenze-kv-prevence-2018.pdf>>. ISSN 1805-4129
2. AL-JAMEIL, Noura – AZIZ KHAN, Farah – FAREED KHAN, Mohammad. , et al. A brief overview of preeclampsia. / *Clin Med Res* [online]. 2014, y. 6, vol. 1, p. 1-7, Available from <<https://www.ncbi.nlm.nih.gov/pmc/articles/PMC3881982/?tool=pubmed>>. ISSN 1918-3003.

</noinclude>

## Eclampsia

**Eclampsia** is an attack of tonic-clonic convulsions in a pregnant woman following previous severe preeclampsia or superimposed preeclampsia. There are also forms without preeclampsia ( eclampsia sine preeclampsia ) or forms without convulsions , only unconsciousness ( eclampsia sine eclampsia ). Seizures occur most often at the end of pregnancy and during childbirth , rarely also in the sixth trimester .

### Pathogenesis

The cause of eclampsia is a generalized spasm in the CNS , which leads to hypoxia and then to brain edema , resulting in morphological changes in the brain tissue.

### Progress [ edit | edit source ]

1. *Prodrome phase* – restlessness, twitching of the face, turning of the bulbs and head to the side, severe headaches , nausea , pain in the epigastrium, vomiting .
2. *The phase of tonic convulsions* - affecting the masticatory muscles , chest muscles and diaphragm ( apnea ), then back muscle spasms - opisthotonus , upper limbs - boxing position, lasts a few seconds.
3. *The phase of clonic convulsions* – the body is reeling in uncoordinated movements, the hands perform a movement reminiscent of tambora drumming, may last several minutes.
4. Coma - after the convulsions subside, the woman falls into a coma , mydriasis , hyporeflexia, deep breathing, after waking up there is amnesia .

- If untreated, the seizure may recur and *status eclampticus* occurs .

## First Aid

The first aid kit is prepared in the delivery room and contains: airway (complete set) to secure the airways, diazepam (we apply 5–10 mg iv) and MgSO<sub>4</sub> 4–6 g/5 min iv. The use of magnesium alone has better results, than using diazepam alone.<sup>[1]</sup>

- We will introduce a nasogastric tube (prevention of aspiration), a permanent catheter, oxygen, and put the woman in a dark room before giving birth.
- If a seizure occurs, regardless of the fetus, we terminate the pregnancy by caesarean section. It is better to bring the woman out of the coma and stabilize her before the operation, but in an urgent situation we also operate in a coma.

## Complications

Complications include CNS hemorrhage, pulmonary edema, circulatory failure, uterine hypertonus, and premature placental abruption with development of DIC, anemia, hepatorenal failure. After managing the acute condition - in the ICU, we monitor, antihypertensive treatment continues, we apply MgSO<sub>4</sub>, we maintain circulation, we monitor. Then we transfer to Sect. six-month-old - we monitor BP every 4 hours, laboratory. After discharge, we check once a week for 6 weeks (obstetrician and internist).

## Chronic hypertension

- **Chronic hypertension**, or **preexisting hypertension**, is defined as an increase in BP before the 20th week of pregnancy;
- there is a history of hypertension even before conception and we repeatedly find higher values;
- findings on the background of the eye (retinopathy), hypertrophy of the heart (LV), changes in renal functions, ... are evidence for this diagnosis;
- often complicated by superimposed preeclampsia.

### We hospitalize a pregnant woman if

- BP corresponds to a severe form of hypertension - above 160/110;
- activation of the underlying disease is present (e.g. pyelonephritis);
- at the first occurrence of proteinuria;
- with a severe form of IUGR.
- Monitoring, laboratory values and other parameters are the same as for preeclampsia.

## Superimposed Preeclampsia

- Rise of systole by 30 and diastole by 15 Torr;
- usually superimposes on already existing chronic hypertension during pregnancy;
- proteinuria appears either as a new symptom or worsens the existing one to values around 2 g/day;
- pregnant care - see preeclampsia.

## HELLP syndrome

HELLP syndrome is a very serious complication of pregnancy with significant mortality and morbidity (up to 40%). The name originated from the English words Hemolysis, Elevated Liver enzymes, Low Platelets. It is described either as a separate disease or as a complication of preeclampsia. It is a state of severe preeclampsia complicated by hemolysis, thrombocytopenia, abnormal peripheral blood smear, and abnormal liver function tests.

## Incidence

In 2–12% of preeclampsia, most often in multiparous couples around the age of 25, most often in the 36th week, in 70% before delivery, in 30% after delivery.

## Pathogenesis

Unclear, probably generalized vasospasm with subsequent MODS (mainly liver, kidney) and activation of coagulation. The result is *microangiopathic thrombocytopenia*.

## Laboratory

- Hemolysis - pathological smear of blood - there are schistocytes and *burr cells* (triangular erythrocytes) - probably formed by flow through the affected vessel, rise of bilirubin above 20 µmol/l, LD (5×), free iron in the serum.
- Elevation of liver tests - mainly AST (2–3×).
- Thrombocytopenia - drop below 100, consumption and destruction.

## Clinical picture

Pain in the epigastrium and in the right hypochondrium , nausea and vomiting dominate . Prodromes – non-specific, flu-like (malaise, fatigue). The advanced stage is manifested by bleeding ( hematuria , bleeding into the GIT ). Weight gain with swelling , hypertension with proteinuria , sometimes jaundice . A fully developed HELLP mimics DIC .

## Differential diagnosis

Acute hepatic steatosis, ITP , HUS , hyperemesis gravidarum, cholecystopathy, viral hepatitis , gastroenteritis , appendicitis , pyelonephritis , renal colic , SLE .

## Complications

DIC (up to 40%), placental abruption , acute respiratory insufficiency, ARDS , ascites , rupture of subcapsular hematoma of the liver, eclampsia , IUGR .

## Treatment

Termination of pregnancy is the only causal treatment. Conservative therapy is for the postpartum period. Expansion of plasma volume, adjustment of coagulation ( antithrombin III , plasma , erymasa, platelets), corticoids (immunosuppression), anticonvulsant prophylaxis (MgSO 4 , valium), antihypertensives , ATB , diet, hepatoprotectants , plasmapheresis ( dialysis ).

## Links

### Related Articles

- Hypertension
- Antihypertensives

### References

1. DULEY, Lelia, David J HENDERSON-SMART and Godfrey JA WALKER. Magnesium sulphate versus diazepam for eclampsia. *Cochrane Database of Systematic Reviews*. 2010, year -, vol. -, p. -, ISSN 1465-1858. DOI: 10.1002/14651858.cd000127.pub2 .

### References

- BENEŠ, George. *Study Materials* [online]. [cit. 2009]. <<http://jirben.wz.cz>>.