

# Hyperplasia of the endometrium

**Endometrial hyperplasia** is one of the most common histological diagnoses in perimenopausal and postmenopausal women.

There is an increase in the number of endometrial glands, which may or may not contain some atypia. Based on the histological analysis of the biopsy performed, we then differentiate between typical and atypical, simplex and complex hyperplasia. Based on the type, we then infer the risk of malignant potential hyperplasia.

## Causes

It most often arises on the basis of the exogenous or endogenous influence of estrogens.

## Speeches

Objevují se abnormality děložního krvácení (intermenstruační krvácení, spotting, hypermenorrhea, oligomenorrhea aj.) v období perimenopauzálním a postmenopauzálním. Některé případy (zejména v období postmenopauzálním) bývají asymptomatické.

## Therapy

Therapy depends on the histological findings. Medicinal therapy is indicated for benign findings, possibly in women of childbearing age. For findings with malignant potential, we proceed to surgical treatment - hysterectomy.

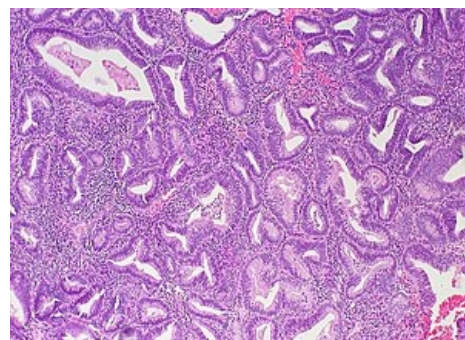
## Links

### Related Articles

- Hyperplastic endometrium (preparation)

### Resources

- CIBULA, D – PETRUŽELKA, L. *Oncogynecology- Kleibl, Z. Cell cycle and apoptosis*. 1. edition. Praha : Grada, 2009. 0 pp. ISBN 978-80-247-2665-6.
- ROZTOČIL, Aleš – BARTOŠ, Pavel, et al. *Modern gynecology*. 1. edition. Praha : Grada, 2011. 508 pp. ISBN 978-80-247-2832-2.
- KOLAŘÍK, Dušan – HALAŠKA, Michael. *Gynecology refresher course*. 2. edition. Praha : Maxdorf, 2011. 0 pp. ISBN 978-80-7345-267-4.



Complex hyperplasia of the endometrium