

# Hyperkeratosis

## Under construction / Forgotten

This article was marked by its author as *Under construction*, but the last edit is older than 30 days. If you want to edit this page, please try to contact its author first (you will find him in the history (<https://www.wikilectures.eu/index.php?title=Hyperkeratosis&action=history>)). Watch the page as well. If the author will not continue in work, remove the template `{{Under construction}}` and the page.

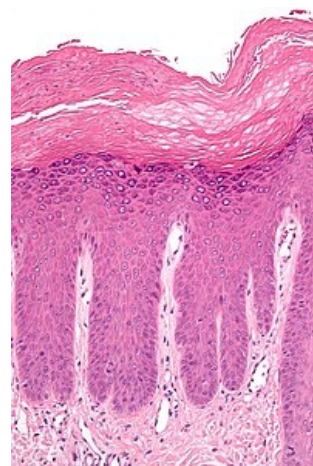
Last update: Saturday, 25 Mar 2023 at 10.35 am.

This article has been translated from WikiSkripta; ready for the **editor's review**.

**Hyperkeratosis** is a thickening of the *stratum corneum* that is often associated with the presence of an abnormal amount of keratin.<sup>[1]</sup>

Hyperkeratosis can be further distinguished:

- **Orthokeratosis** (or *orthokeratotic hyperkeratosis* or *orthohyperkeratosis*) is characterized by normal keratinocyte maturation.
- **Parakeratosis** (or *parakeratotic hyperkeratosis*) is characterized by pathological maturation of keratinocytes, as cell nuclei are present in their cytoplasm in the stratum corneum.



## Links

## Related Articles

- Histopathological changes in the skin

## References

1. KUMAR VINAY, ABBAS ABUL K, FAUSTO NELSON, ROBBINS STANLEY L and COTRAN RAMZI S. *Robbins and Cotran Pathologic Basis of Disease*. 7th ed. Philadelphia: Elsevier Saunders, 2005, xv, 1525 p.

## References

- ŠTORK, Jiří. *Dermatovenerologie*. 1. edition. Praha : Galén, Karolinum, 2008. 502 pp. ISBN 978-80-7262-371-6.