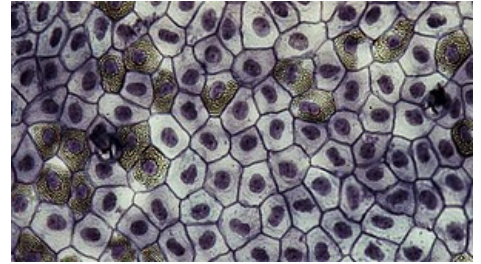


Histology MCQs/Epithelial Tissue

1 Assume classification of epithelia according to the morphology. Which type of epithelium is epithelium of **endocrine gland**?

- ☐ In all cases, endocrine gland are composed of the trabecular epithelium
- ☐ In all cases, endocrine gland are composed of the planar epithelium
- ☐ Approximately half of exocrine gland is composed of trabecular epithelium and the rest is composed of the planar epithelium
- ☐ Usually trabecular; the exception is the thyroid gland which is composed of the planar epithelium



Looking from the lumen, all planar epithelia look similarly.

2 Which structure is associated with the **basal body**?

- ☐ Basal annealing
- ☐ Microvillus
- ☐ Villus
- ☐ Cilium

3 Which structure forms the **brush border**? (i.e., "*Of which structures is composed the **brush border**?*")

- ☐ Secretory granules
- ☐ Basal annealing
- ☐ Microvilli
- ☐ Cilia

4 Which type of the epithelium are cells which are main site of gas exchange (type I pneumocytes)?

- ☐ Pseudostratified columnar epithelium
- ☐ Simple cuboidal epithelium
- ☐ Simple squamous epithelium
- ☐ Reticular epithelium

5 Which is embryonic origin of epithelial tissues?

- ☐ Three germ layers, neural tube or neural crests
- ☐ Three germ layers or neural crests
- ☐ Three germ layers or neural tube
- ☐ Three germ layers only

6 Imagine resorptive epithelium. Which type of epithelium is it (usually) according to the morphological classification (to the structure)?

- ☐ Pseudostratified columnar epithelium
- ☐ Stratified columnar epithelium
- ☐ Simple columnar epithelium
- ☐ Simple squamous epithelium

7 Imagine stratified columnar epithelium. Are there some cells of roughly cubic shape in this epithelium?

- ☐ Yes, they are in the intermediate layer (layer between basal and superficial layers)
- ☐ Yes, they are dissipated among cells of the outermost layer
- ☐ Yes, they are in the basal layer
- ☐ No, they are not present

8 Which are main adhesive proteins of **desmosomes**?

- ☐ E-cadherin and catenin complex
- ☐ Desmoglein and desmocollins
- ☐ Claudins and occludins
- ☐ Integrins

9 Which are main adhesive proteins of **tight junctions**?

- ☐ E-cadherin and catenin complex
- ☐ Desmoglein and desmocollins
- ☐ Claudins and occludins
- ☐ Integrins

10 Which are main adhesive proteins of **zonulae adherentes**?

- ☐ E-cadherin and catenin complex
- ☐ Desmoglein and desmocollins
- ☐ Claudins and occludins
- ☐ Integrins

11 Which staining is most appropriate for **mucus** (product of mucinous cells)?

- ☐ Masson's trichrome
- ☐ Alcian blue
- ☐ Anilin blue
- ☐ Orcein

12 Only one statement about the stratified squamous epithelium is correct. Which one?

- ☐ Cells of the outermost layer, i.e. layer farthest from the basement membrane, are squamous (flat)
- ☐ Cells of the outermost layer, i.e. layer farthest from the basement membrane, are polygonal (polyhedral)
- ☐ Cells of the innermost layer, i.e. layer closest to the basement membrane, are squamous (flat)
- ☐ Cells of the innermost layer, i.e. layer closest to the basement membrane, are polygonal (polyhedral)

13 Which staining highlights **secretory granules of mucous cells** the best?

- ☐ Heidenheins iron hematoxylin
- ☐ Feulgen's reaction
- ☐ PAS reaction
- ☐ AZAN

14 How are called sensory cells (receptors) of epithelial origin?

- ☐ Primary sensory cells
- ☐ Secondary sensory cells
- ☐ Tertiary sensory cells
- ☐ Quaternary sensory cells

15 The most common type of secretion of exocrine cells is:

- ☐ All possible types of secretion are roughly equally frequent
- ☐ Merocrine secretion
- ☐ Holocrine secretion
- ☐ Apocrine secretion

16 How to describe product of **serous glands**?

- ☐ It is of high viscosity because it is rich on polysaccharides
- ☐ It is of low viscosity because it is rich on polysaccharides
- ☐ It is of high viscosity because it is rich on proteins
- ☐ It is of low viscosity and rich on proteins

17 What does in meat that the exocrine gland is **branched**?

- ☐ Several secretory parts are connected to one duct; these duct connect to bigger and bigger duct, the biggest duct opens to the surface
- ☐ Only one secretory part is connected to one duct; these duct connect to bigger and bigger duct, the biggest duct opens to the surface
- ☐ Secretory part opens directly to the surface, or it is connected with the surface by the short duct only
- ☐ Several secretory parts are connected to one short duct; this duct opens to the surface

18 What does in meat that the exocrine gland is **COMPOUND**?

- ☐ Several secretory parts are connected to one duct; these duct connect to bigger and bigger duct, the biggest duct opens to the surface

- ☐ Only one secretory part is connected to one duct; these duct connect to bigger and bigger duct, the biggest duct opens to the surface
- ☐ Secretory part opens directly to the surface, or it is connected with the surface by the short duct only
- ☐ Several secretory parts are connected to one short duct; this duct opens to the surface

19 Which statement describes a **holocrine secretory cell** the best?

- ☐ Holocrine secretory cell is an endocrine cell of which apical part is fulfilled by its own product. Main secretion is based on releasing of apical part of the cell and its subsequent decay.
- ☐ Holocrine secretory cell is an exocrine cell of which apical part is fulfilled by its own product. Main secretion is based on releasing of apical part of the cell and its subsequent decay.
- ☐ Holocrine secretory cell is an endocrine cell which is fulfilled by its own product. Main secretion is based on releasing of whole cell and its subsequent decay.
- ☐ Holocrine secretory cell is an exocrine cell which is fulfilled by its own product. Main secretion is based on releasing of whole cell and its subsequent decay.

20 Where are usually **myoepithelial cells**?

- ☐ In secretory part of glands between secretory cells and the basement membrane
- ☐ In secretory part of glands as the layer which is closest to the lumen
- ☐ In secretory part of glands dissipated among secretory cells
- ☐ In secretory part of glands out of the basement membrane

21 Which organ contains **stratified squamous epithelium with keratinization**?

- ☐ Mucosa of oral cavity
- ☐ Oesophagus
- ☐ Larynx
- ☐ Skin

22 In which organ do we have **serous acini**?

- ☐ Inside the exocrine pancreas because exocrine pancreas produces viscous and chemically inert mucus
- ☐ Inside the exocrine pancreas because exocrine pancreas produces insuline and glucagon
- ☐ Inside the exocrine pancreas because exocrine pancreas produces plenty of enzymes
- ☐ Inside the exocrine pancreas because exocrine pancreas produces fatty sebaceum

23 Which description of germinal epithelium is the most accurate?

- ☐ Germinal epithelium secure appropriate environment for development of oocytes
- ☐ Germinal epithelium secure appropriate environment for development of sperms
- ☐ Germinal epithelium is source of new sperms
- ☐ Germinal epithelium is source of new oocytes

24 Which gland uses holocrine type of secretion?

- ☐ Sublingual salivary gland
- ☐ Parotid salivary gland
- ☐ Skin sebaceous gland
- ☐ Skin sweat gland

25 Which of following statements is the best description of **gap junction** (nexus)?

- ☐ Cell addhesion involved mainly in a barrier avoid free diffusion along epithelial cells
- ☐ Cell addhesion involved mainly in exchange of small molecules and ions between cells
- ☐ Cell addhesion involved mainly in anchoring the cell to the basement membrane
- ☐ Cell addhesion involved mainly in mechanical stability and resistance

26 Which of following statements is the best description of **zonula occludens**?

- ☐ Cell addhesion involved mainly in a barrier avoid free diffusion along epithelial cells
- ☐ Cell addhesion involved mainly in exchange of small molecules and ions between cells
- ☐ Cell addhesion involved mainly in anchoring the cell to the basement membrane
- ☐ Cell addhesion involved mainly in mechanical stability and resistance

27 Which of following terms **do not denote** one of main ("root") categories ofn classification of epithelial tissue according to the structure?

- ☐ Transitional epithelium

- ☐ Trabecular epithelium
- ☐ Reticular epithelium
- ☐ Planar epithelium

28 Which sentence is the most appropriate description of **pseudostratified columnar epithelium**?

- ☐ Only cells in the basal layer are attached to the basement membrane, cells of higher layer are not attached to the basement membrane
- ☐ All cells are attached to the basement membrane, but nuclei of these cells are in different distance from the basement membrane
- ☐ Basement membrane of this type of epithelium has some cylindrical pores
- ☐ All cells are of columnar shape, cells are in several layers

29 Which statement about absorptive epithelium is **not true**?

- ☐ Absorptive function of epithelium is important function of epithelium of large intestine
- ☐ Absorptive function of epithelium is important function of epithelium of small intestine
- ☐ Absorptive function of epithelium is main function of epithelium of tubules in kidney
- ☐ Absorptive function of epithelium is main function of epithelium of skin (epidermis)

30 Which statement about the endocrine secretion is **true**?

- ☐ Product of endocrine gland can be released via holocrine secretion
- ☐ Product of endocrine gland can be either serous or mucinous
- ☐ Product of endocrine gland is released to the blood
- ☐ Product of endocrine gland is released to the duct

31 Which statement about the exocrine secretion is **true**?

- ☐ Product of exocrine gland is released into ducts or directly onto the surface
- ☐ Product of exocrine gland contains in all cases huge amount of enzymes
- ☐ Product of exocrine gland is usually released to the blood
- ☐ Product of exocrine gland is usually called a hormone

32 Which structure inside the cell is responsible for contractility of myoepithelial cells?

- ☐ Network composed of intermediate filaments
- ☐ Network composed of actin filaments
- ☐ Network composed of cytokeratins
- ☐ Network composed of microtubules

33 Which type of collagen is main part of **basal lamina**?

- ☐ Type I collagen
- ☐ Type II collagen
- ☐ Type III collagen
- ☐ Type IV collagen

34 Which type of cytoskeleton forms main inner structure of **cilia**?

- ☐ Actin filaments associated with type I myosin and other proteins
- ☐ Microtubules associated with dyneins and other proteins
- ☐ Microvilli have no obvious inner structure
- ☐ Cytokeratins associated with ubiquitin

35 Which type of epithelium according to the most pronounced **function** is epidermis?

- ☐ Stratified squamous epithelium without keratinization
- ☐ Stratified squamous epithelium with keratinization
- ☐ Secretory type of epithelium
- ☐ Covering type of epithelium

Submit

- List of all tests: Histology MCQs
- Portal:Histology