

Hernia

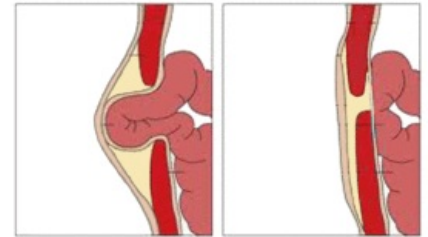
Hernia is a condition where an organ (or organs) is pathologically displaced from its natural location. Most often, this means pushing the organs of the abdominal cavity through weakened areas of the abdominal wall. However, this is a general term - there is, for example, herniation of the intervertebral disc. The main clinical significance of abdominal hernias lies in the risk of entrapment of their contents (so-called incarceration), when the vessels supplying the given organ with blood are compressed, which then suffers from ischemia and after a few hours necrosis may occur. Part of the whole process is inflammation, which can spread to the peritoneum with the development of life-threatening peritonitis. Hernia is treated surgically, and herniation is a reason for immediate operation (surgery within 6 hours is optimal). The most common are inguinal (79.8%), femoral (21.1%) and umbilical (5%) hernias.

Structure

For most hernias, we recognize:

- hernia gate,
- hernia sac,
- hernia contents.

The content of an inguinal hernia is most often the small intestine (enterocele) or the omentum (epiplocele). But it can also be a Meckel's diverticulum (so-called Littre's hernia) or just part of the circumference of the small intestine (so-called Richter's mural hernia). An inguinal hernia in girls may contain an ovary (ovariocele). A diaphragmatic hernia, on the other hand, can involve almost any organ of the abdominal cavity (stomach, liver, spleen, kidneys).



Umbilical hernia growth

Division

By location

- external
- internal

By origin

- congenital (congenital hernias)
- acquired (acquired hernias)

By presence of the sac

- true (sac is present)
- false (sac is not present)

By repossability

- freely reponible (hernia libera)
- irreponible
 - incarceration (incarcerated hernia)
 - adhesions between the sac and the contents of the hernia (hernia accreta)
 - too bulky hernia (hernia permagna)

Types of hernia

- inguinal (direct or indirect)
- umbilical
- epigastric/supraumbilical
- supravesical
- femoral
- obturator
- perineal
- sciatic
- hiatal
- sliding
- paraesophageal
- lumbal
- parastomal

- in a scar
- diaphragmatic
 - congenital diaphragmatic hernia
 - hiatal hernia
- paraduodenal
- pericecal
- hernia in foramen of Winslow
- transmesenteric
- intersigmoid

Links

Related articles

- Muscle hernia
- Inguinal hernias
- Femoral hernia
- Umbilical hernia

References

- ČIHÁK, Radomír – GRIM, Miloš. *Anatomy*. 3. edition. Prague : Grada, 2013. 0 pp. ISBN 978-80-247-4788-0.