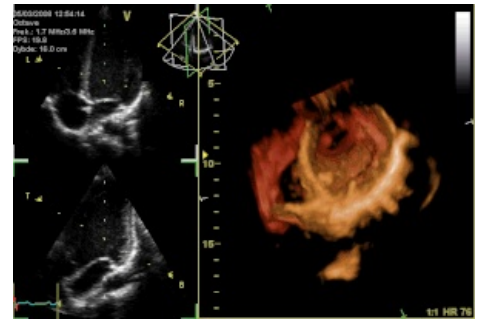


# Heart valves

Heart valves are valves that ensure one-sided flow of blood in the heart.

**They are not innervated** and they are **avascular** (they open and close based on a pressure gradient). From a histological point of view, these are endocardial duplications. They are formed by an internal fibrous plate (collagen and elastic fibers), on the surface they are covered by endothelium. They are connected to the fibrous rings of the heart skeleton. In the heart we find 4 heart valves, they are:

1. **tricuspid valve** (valva atrioventricularis dextra seu tricuspidalis) - between the right atrium and the right ventricle;
2. **pulmonary valve** (valva trunci pulmonalis) - between the right ventricle and the pulmonary artery;
3. **mitral valve** (valva atrioventricularis sinistra seu bicuspidalis seu mitralis) - between left atrium and left ventricle;
4. **aortic valve** (valva aortae) - between the left ventricle and the aorta.



2D and 3D image of the heart taken by an echocardiograph. The 2D image shows the tricuspid and mitral valve (top) and the aortic and mitral valve (bottom).

## Links

### Related links

- Heart
- Heart/histology
- Heart valves diseases

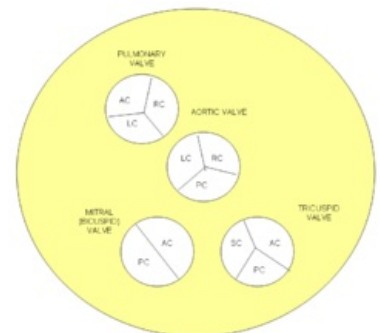
### External sources

- Chlopeň (česká wikipedie)

## Bibliography

- KONRÁDOVÁ, Václava. *Funkční histologie*. 2. edition. H & H, 2000. 291 pp. ISBN 978-80-86022-80-2.
- JUNQUEIRA, Carlos L. *Základy histologie*. 1. edition. H & H, 2002. 502 pp. ISBN 80-85787-37-7.
- STINGL, Josef. *Oběhový systém : Histologie* [online]. Oddělení histologie a embryologie 3. lékařské fakulty v Praze, ©2005. [cit. 2010-09-20]. <<http://histologie.lf3.cuni.cz/histologie/materialy/doc/obeh-ho.pdf>>.
- KACHLÍK, David – JELÍNEK, Štěpán. *Srdce : Morfologický seminář* [online]. ©2004. [cit. 2010-09-20]. <<https://www.lf3.cuni.cz/histologie/materialy/ppt/srdce.ppt>>.

## References



Scheme of heart valves