

# Hairy cell leukemia

## Definition

Hairy cell leukemia is a chronic leukemia characterized by the presence of so-called **hairy cells**. Hairy cells are characterized by the appearance of mononuclear cells with fine hair protrusions of cytoplasm on the cell surface and the presence of **tartrate-resistant acid phosphatase in the cytoplasm**. Their non-tumor equivalent is not known (previously was considered origin from endothelium - the older name for the disease was leukemic reticuloendotheliosis, today they are considered atypical B-lymphocytes (rarely they can also originate from T-lymphocytes)). This leukemia is **classified as Non-Hodgkin's lymphoma** with low malignancy, they have some properties of macrophages (ability of Phagocytosis) and of lymphocytes (they carry surface Antibodies and react with monoclonal antibodies against B-lymphocytes). **Occurs in** adults, **especially in men**.

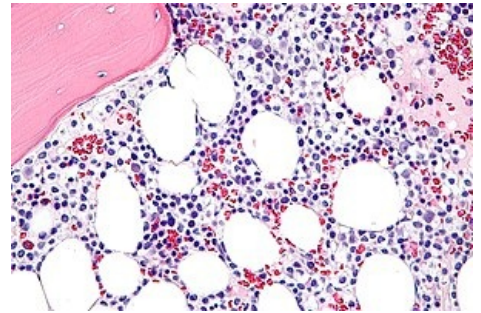
## Microscopic findings

### Bone marrow

- **Massive infiltration** of networked lymphoid and monocytic cells,
- original hematopoiesis is **supressed**, number of mastocytes and reticular fibers is increased,
- massive infiltration of bone marrow does not correlate with blood count.

### Extramedullary tissues

1. **Spleen** – **diffuse infiltration**, lymphocytes increase the size of red pulp (so-called angiomatoid transformation of the spleen),
2. **Liver** – tumorous **infiltration less marcant** than in spleen,
3. **nodes** – **usually no infiltration**.



Hairy cell leukemia

## References

### Related articles

- Leukemia
- Acute lymphocytic leukemia
- Acute myeloid leukemia
- Chronic myeloid leukemia
- Chronic lymphocytic leukemia

### Source

- PASTOR, Jan. *Langenbeck's medical web page* [online]. ©2006. [cit. 30.9.2010]. <<http://langenbeck.webs.com/pathologie.htm>>.