

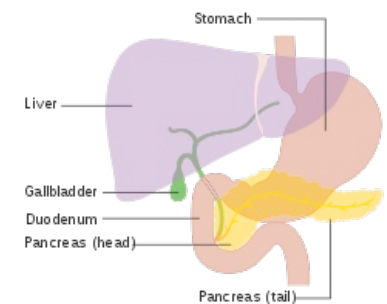
Gallbladder

The **gallbladder** (*vesica fellea*, *vesica biliaris*) is located on the underside of the liver in the **fossa vesicae biliaris**. The gallbladder is completely or only partially covered by the peritoneum, which passes from the visceral surface of the liver. The main function of the gallbladder is to **store the bile** that flows from the liver and concentrate it.

Structure

We distinguish four parts of the gallbladder: *fundus*, *corpus*, *collum vesicae biliaris* and *ductus cysticus*.

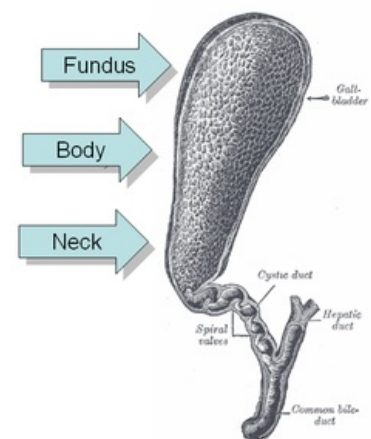
- **Fundus vesicae biliaris** - the bottom of the gallbladder, pointing forward and down, partially protruding over the edge of the liver. Ventrally from it, there is the anterior abdominal wall, caudally is the colon transversum. It passes freely into the *corpus vesicae biliaris*. The fundus projects to the anterior abdominal wall inward from the right medioclavicular line. It is therefore accessible by palpation - **McMurphy point**.
- **Corpus vesicae biliaris** - lies in the *fossa vesicae biliaris*. From above it insists on *flexura coli dextra*. It narrows dorsally and turns into a *collum vesicae biliaris*. The point of transition of the body into the neck is called the *gallbladder infundibulum*. It is the point of contact with the *pars superior duodenum*.
- **Collum vesicae biliaris** - dorsal narrowed part, freely passing into the gallbladder outlet.
- **Ductus cysticus** - is 2-3 cm long, followed by a connection with the *ductus hepaticus communis* to form the *ductus choledochus*. Inside the ductus cysticus is the *algae plica spiralis*, which allows bile to flow in both directions. It is an obstacle to the passage of gallstones.



Gallbladder

Functions of gallbladder

Bile is concentrated by the epithelial lining of the gallbladder, which has a high absorption capacity. The process is based on the active transport of ions into the intercellular cleft. At the basolateral membrane, $\text{Na}^+/\text{K}^+\text{ATPase}$ drains sodium cations out of the cell. Sodium is then exchanged for H^+ on the luminal side, which significantly increases bile acidity. In the gallbladder lumen, the hydrogen cation combines with HCO_3^- to form water and carbon dioxide. Na^+ transfer is accompanied by paracellular and transcellular Cl^- transport. The ions entrain with them also water, which increases the concentration of other components in the bile (e.g. cholesterol, bile acids, bilirubin) inside the gallbladder. The resulting concentration is up to twelve times higher ^[1], the pH can drop from 8.2 to 6.5. ^[1]



Structure of gallbladder

Histology

The gallbladder wall consists of *tunica mucosa*, *tunica muscularis* and *tunica serosa*.

Mucosa tunic

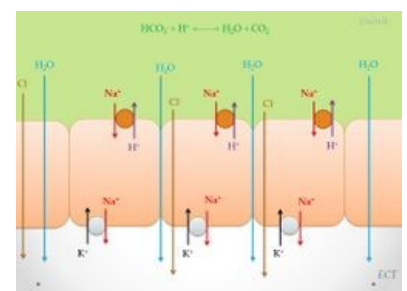
The mucous membranes form *algae*, which are especially noticeable in the empty gallbladder because their height depends on the amount of gallbladder content. In some places, **indentations** are formed, which resemble pockets and extend to the tunica muscularis. These cavities are called **Rokitansky - Aschoff sinuses**.

On the entire surface of the mucosa, the gallbladder is lined with **a single-layer cylindrical epithelium with microvilli**, which is equipped with connecting complexes. Mitochondria are abundant in epithelial cells. Epithelial cells are able to secrete mucus to a small extent. In addition, they are able to absorb water and thus help to concentrate bile. According to this function, we can say that it is a **resorption epithelium**. At the neck of the gallbladder, mucinous glands appear in its wall, which is responsible for most of the mucus in the bile.

The **lamina propria mucosae** consist of a sparse collagen ligament. **Lamina muscularis mucosae is missing!**

Muscularis tunic

The muscle layer is thin and the smooth muscle cells are oriented circularly. Muscle is important for bile secretion. Muscle contractions are caused by **cholecystokinin** and the autonomic nervous system.



Scheme of concentrating of the bile

Serous tunic

The gallbladder is attached to the liver with a thick fibrous layer, so it does not have a serous coating, but an adventitia. The opposite side is covered with a typical serosal layer.

Links

Related articles

- Biliary tract
- Cholelithiasis

Used literature

- ČIHÁK, Radomír. Anatomie II. 2. vydání. Praha : Grada, 2001. 488 s. ISBN 80-247-0143-X
- KITTNAR, Otomar, et al. Lékařská fyziologie. 1. vydání. Praha : Grada, 2011. 790 s. ISBN 978-80-247-3068-4.
- TROJAN, Stanislav, et al. Lékařská fyziologie. 4. vydání. Praha : Grada, 2003. 771 s. ISBN 80-247-0512-5
- JUNQUEIRA, L., Robert KELLEY a José CARNEIRO. *Základy histologie*. - vydání. H+H, 1997. 502 s. ISBN 9788085787375 (<https://www.wikilectures.eu/w/Special:BookSources?isbn=9788085787375>).
- LÜLLMANN-RAUCH, Renate. *Histologie*. - vydání. Grada Publishing a.s., 2012. 556 s. ISBN 9788024737294.

Reference

1. TROJAN, Stanislav a ET AL.. *Lékařská fyziologie*. 4. vydání. Praha : Grada, 2003. 771 s. s. 354-357. ISBN 80-247-0512-5 (<https://www.wikilectures.eu/w/Special:BookSources?isbn=80-247-0512-5>).