

# Formations in front of the medial ankle

The space in front of the medial ankle is bounded by **the retinaculum musculorum extensorum superius et inferius** (ventrally) and the **malleolus medialis** (dorsally). The saphenous vein and the saphenous nerve run superficially through both retinacula , and the tendon of the **tibialis anterior muscle** runs deep below the retinacula.

For easy memorization, the mnemonic tool **SAMANTA** is used - vena **SA**phena **M**agna, **N**ervus saphenus, tendon musculus **T**ibialis **A**nterior.

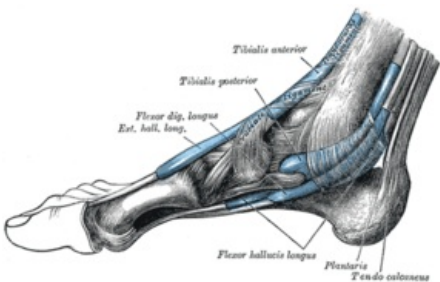
## links

### Related articles

- Formations behind the lateral ankle
- Formations behind the medial ankle
- Anatomy mnemonics

### References

- GRIM, Miloš and Rastislav DRUGA. *Basics of anatomy: 5. Anatomy of body regions*. 1st edition. Prague: Galén, 2008. 119 pp. ISBN 978-80-7262-179-8 .
- CIHÁK, Radomír. *Anatomy 1st* 3rd ed. Prague: Grada Publishing, as, 2011. 552 pp. Vol. 1. ISBN 978-8-247-3817-8 .



Formations in front of the medial ankle

<b>Bordered dorsally</b>	medial malleolus
<b>Bordered ventrally</b>	the retina of the extensor muscles above and below
<b>Contents</b>	v. saphena magna , n. saphenus, tendon m. tibialis anterior
<b>aid</b>	SAMANTHA