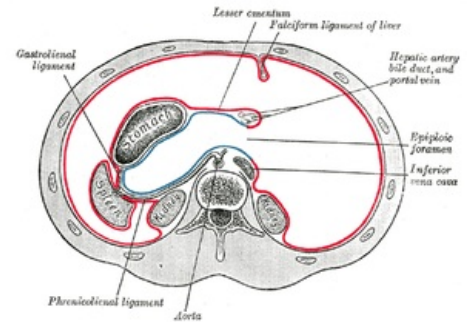


Foramen omentale

The **foramen omentale** (or *foramen epiploicum* , *foramen Winslowi*) is a physiological communication between the **peritoneal cavity** and the **omental bursa**.

Borders:

- **cranially** : *caudate lobe of the liver* ;
- **ventrally** : *lig. hepatoduodenale* , through which *v. portae* (back), *a. hepatica propria* (front left) and *ductus choledochus* (front right) ;
- **dorsally** : *v. cava inferior* and *lig. hepatorenal* ;
- **caudally** : upper edge of *pars superior duodeni* and non-constant peritoneal fold - *lig. duodenorenal* .



Horizontal section through the abdominal cavity at the level of the *foramen omentale*

Links

Related articles

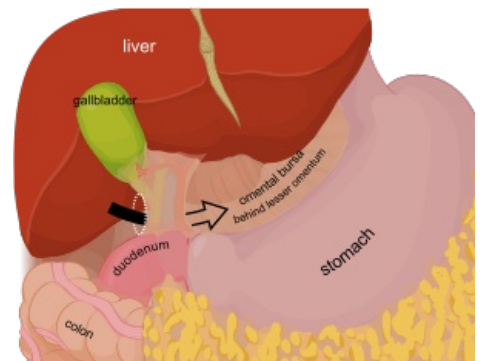
- Duodenum
- Stomach
- Bursa omentalis

External links

- Foramen omentale on English Wikipedia (https://en.wikipedia.org/wiki/Omental_foramen)

References

- GRIM, Miloš – DRUGA, Rastislav. *Základy anatomie : 5. Anatomie krajín těla*. 1. edition. Praha : Galén, 2008. ISBN 978-80-7262-179-8.



Entry into the omental bursa (black arrow) through the foramen omentale (white oval)