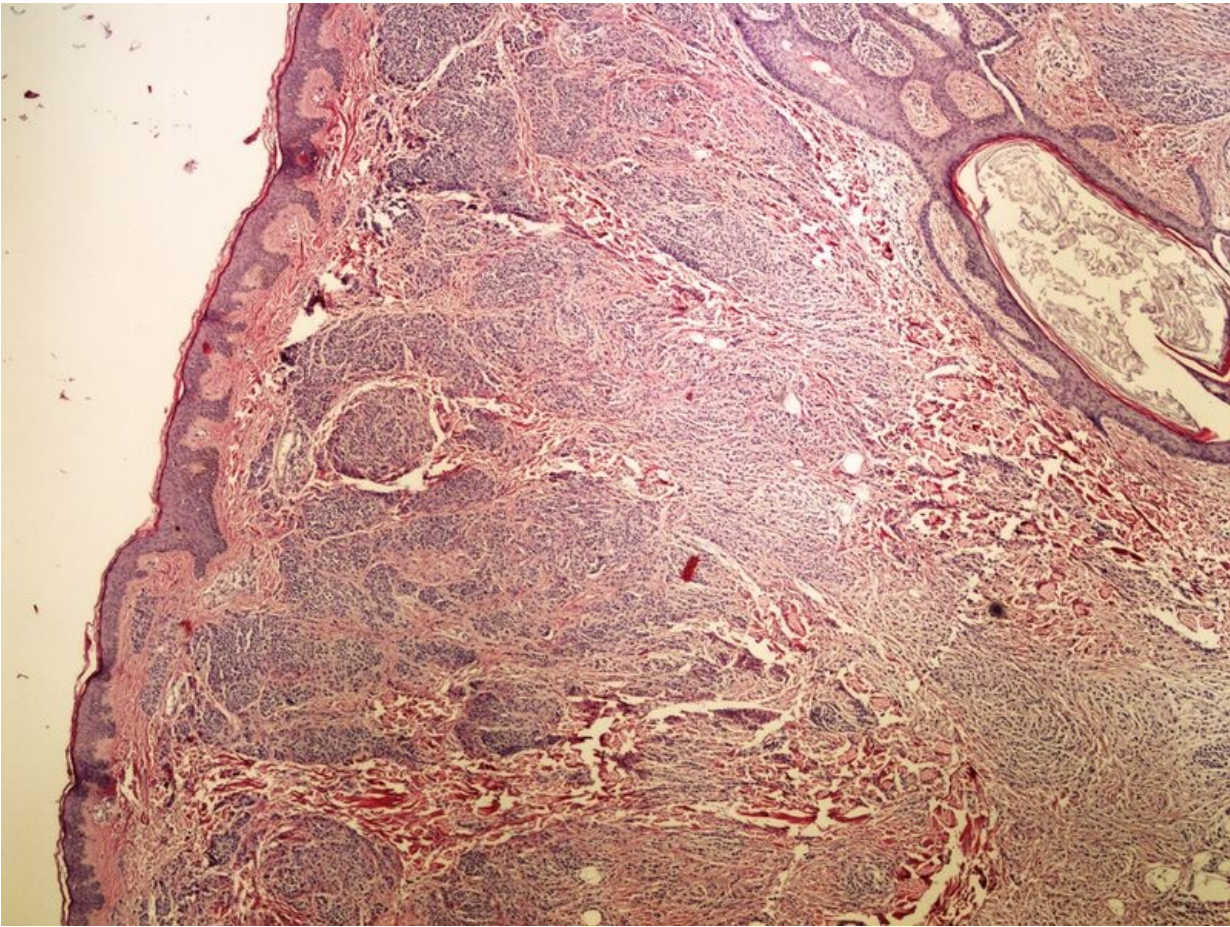


File:Z 11-6 intradermal mole intradermalni pigmentovy nevus 20x oznaceno.jpg



Size of this preview: 800 × 600 pixels.

Original file (2,560 × 1,920 pixels, file size: 3.69 MB, MIME type: image/jpeg)

 [Open in Media Viewer](#) 

Summary

Description

Write a description here

Author

Author's name and surname

Source

Source web address or "own work"

Date

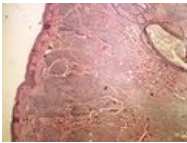
Date

Licensing

 Creative Commons Attribution 4.0 Unported (<http://creativecommons.org/licenses/by/4.0/deed.en>)

File history

Click on a date/time to view the file as it appeared at that time.

	Date/Time	Thumbnail	Dimensions	User	Comment
current	16:37, 9 May 2023		2,560 × 1,920 (3.69 MB)	TomasBarta (talk contribs)	{{File description = Write a description here author = Author's name and surname source = Source web address or "own work" date = Date }}

You cannot overwrite this file.

File usage

The following 2 pages use this file:

- Module GFPP - Practice no. 13
- OZPP Module - Practice Number 13

Metadata

This file contains additional information, probably added from the digital camera or scanner used to create or digitize it.

If the file has been modified from its original state, some details may not fully reflect the modified file.