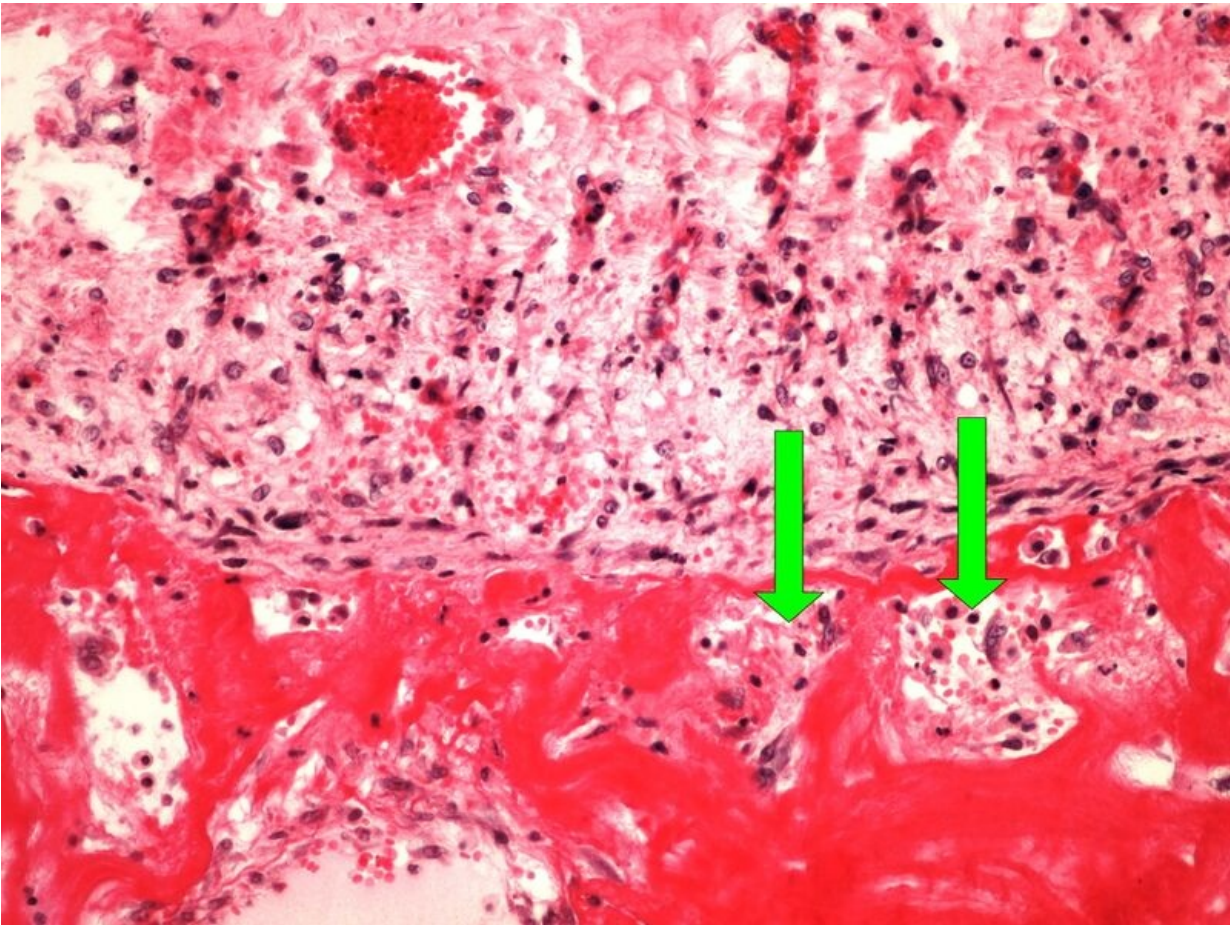


File:Z6-7 chronic fibrinous pericarditis chronicka fibrinozni perikarditis 20x oznaceno.jpg



Size of this preview: 800 × 600 pixels.

Original file (2,560 × 1,920 pixels, file size: 4 MB, MIME type: image/jpeg)

Summary

Description

Author

Zef (MUDr. Jonáš Dyba)

Source

own work

Date

Licensing

Only for direct use at WikiLectures.eu site.

File history

Click on a date/time to view the file as it appeared at that time.

	Date/Time	Thumbnail	Dimensions	User	Comment
current	20:40, 28 May 2023		2,560 × 1,920 (4 MB)	Farahani (talk contribs)	{{File description = author = Zef (MUDr. Jonáš Dyba) source = own work date = }}

You cannot overwrite this file.

File usage

The following 2 pages use this file:

- Module GFPP - Practice no. 7
- OZPP Module - Practice Number 7

Metadata

This file contains additional information, probably added from the digital camera or scanner used to create or digitize it.

If the file has been modified from its original state, some details may not fully reflect the modified file.