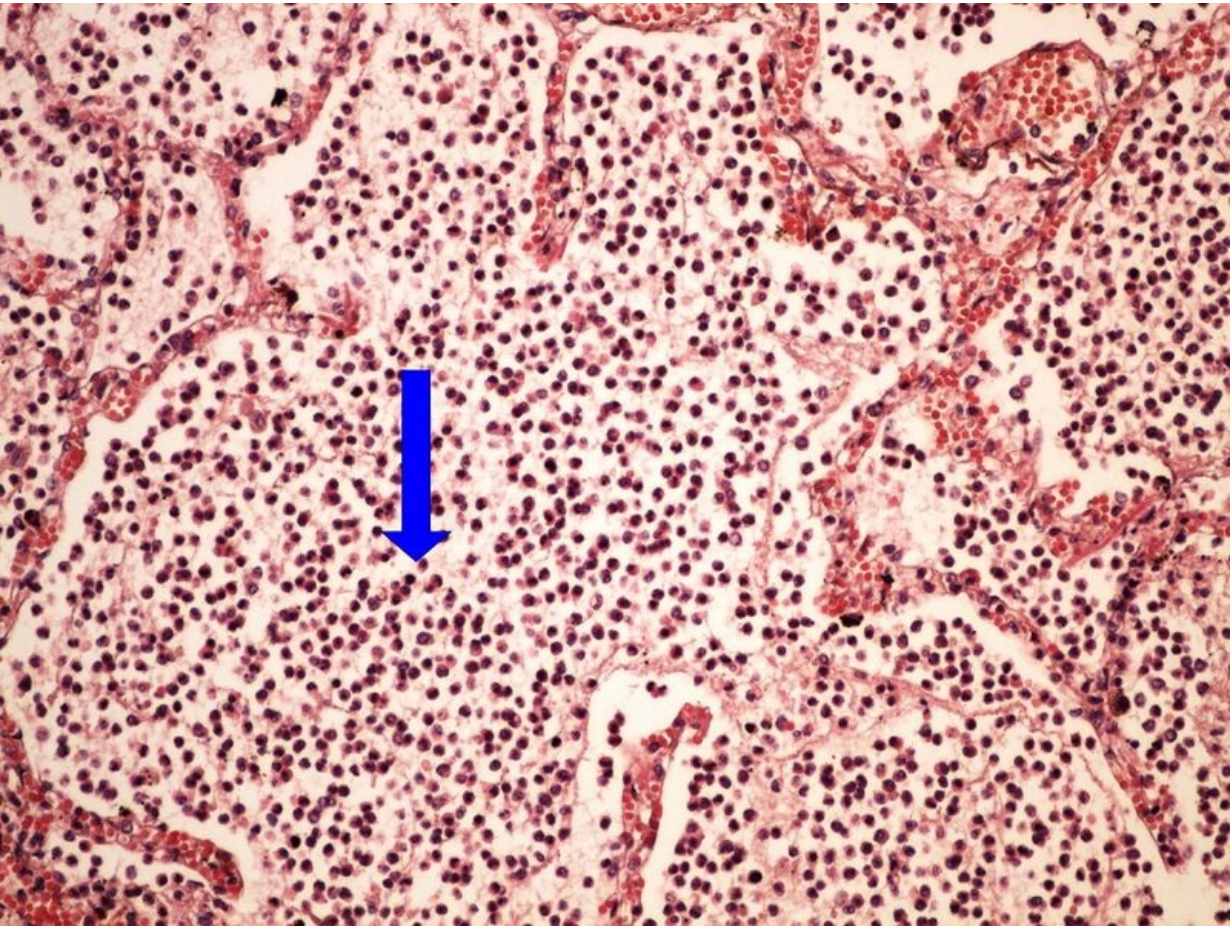


# File:Z6-1 acute bronchopneumonia akutni kataralni bronchopneumonie 20x oznaceno.jpg



Size of this preview: 800 × 600 pixels.

Original file (2,560 × 1,920 pixels, file size: 4 MB, MIME type: image/jpeg)

## Summary

### Description

#### Author

Zef (MUDr. Jonáš Dyba)

#### Source

own work

#### Date

## Licensing

Only for direct use at WikiLectures.eu site.

## File history

Click on a date/time to view the file as it appeared at that time.

|         | Date/Time          | Thumbnail | Dimensions           | User                       | Comment  |
|---------|--------------------|-----------|----------------------|----------------------------|--|
| current | 01:41, 29 May 2023 |           | 2,560 × 1,920 (4 MB) | Farahani (talk   contribs) | {{File  description =  author = Zef (MUDr. Jonáš Dyba)  source = own work  date = }} |

You cannot overwrite this file.

## File usage

The following 2 pages use this file:

- Module GFPP - Practice no. 6
- OZPP Module - Practice Number 6

## **Metadata**

This file contains additional information, probably added from the digital camera or scanner used to create or digitize it.

If the file has been modified from its original state, some details may not fully reflect the modified file.