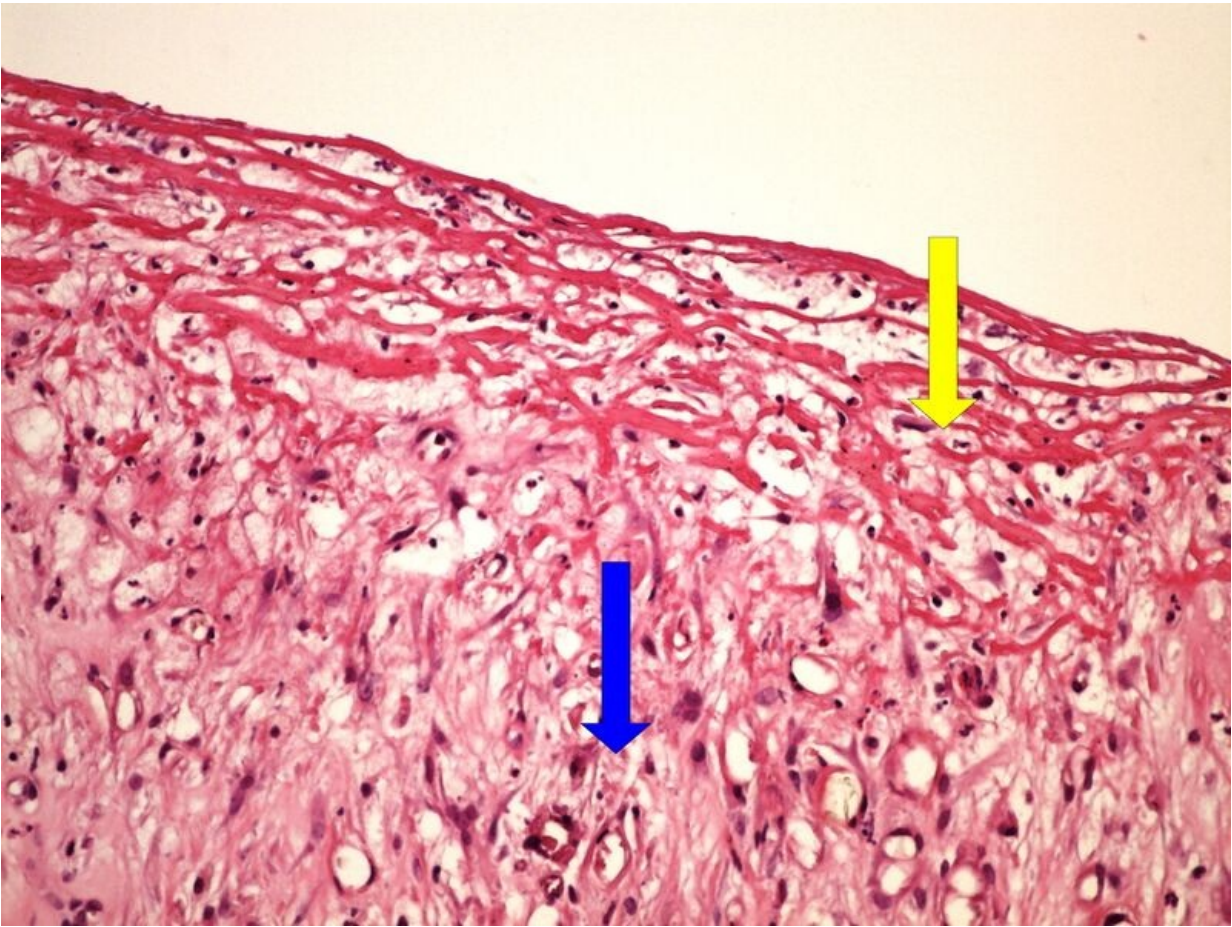


File:Z6-13 chronic skin ulcer granularni tkan spodiny bercoveho vreu 20x oznaceno.jpg



Size of this preview: 800 × 600 pixels.

Original file (2,560 × 1,920 pixels, file size: 3.95 MB, MIME type: image/jpeg)

Summary

Description

Write a description here

Author

Zef (MUDr. Jonáš Dyba)

Source

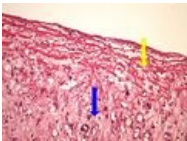
own work

Date

Date

File history

Click on a date/time to view the file as it appeared at that time.

	Date/Time	Thumbnail	Dimensions	User	Comment
current	21:18, 28 May 2023		2,560 × 1,920 (3.95 MB)	Farahani (talk contribs)	{{File description = Write a description here author = Author's name and surname source = Source web address or "own work" date = Date }}

You cannot overwrite this file.

File usage

The following 2 pages use this file:

- Module GFPP - Practice no. 7

- OZPP Module - Practice Number 7

Metadata

This file contains additional information, probably added from the digital camera or scanner used to create or digitize it.

If the file has been modified from its original state, some details may not fully reflect the modified file.