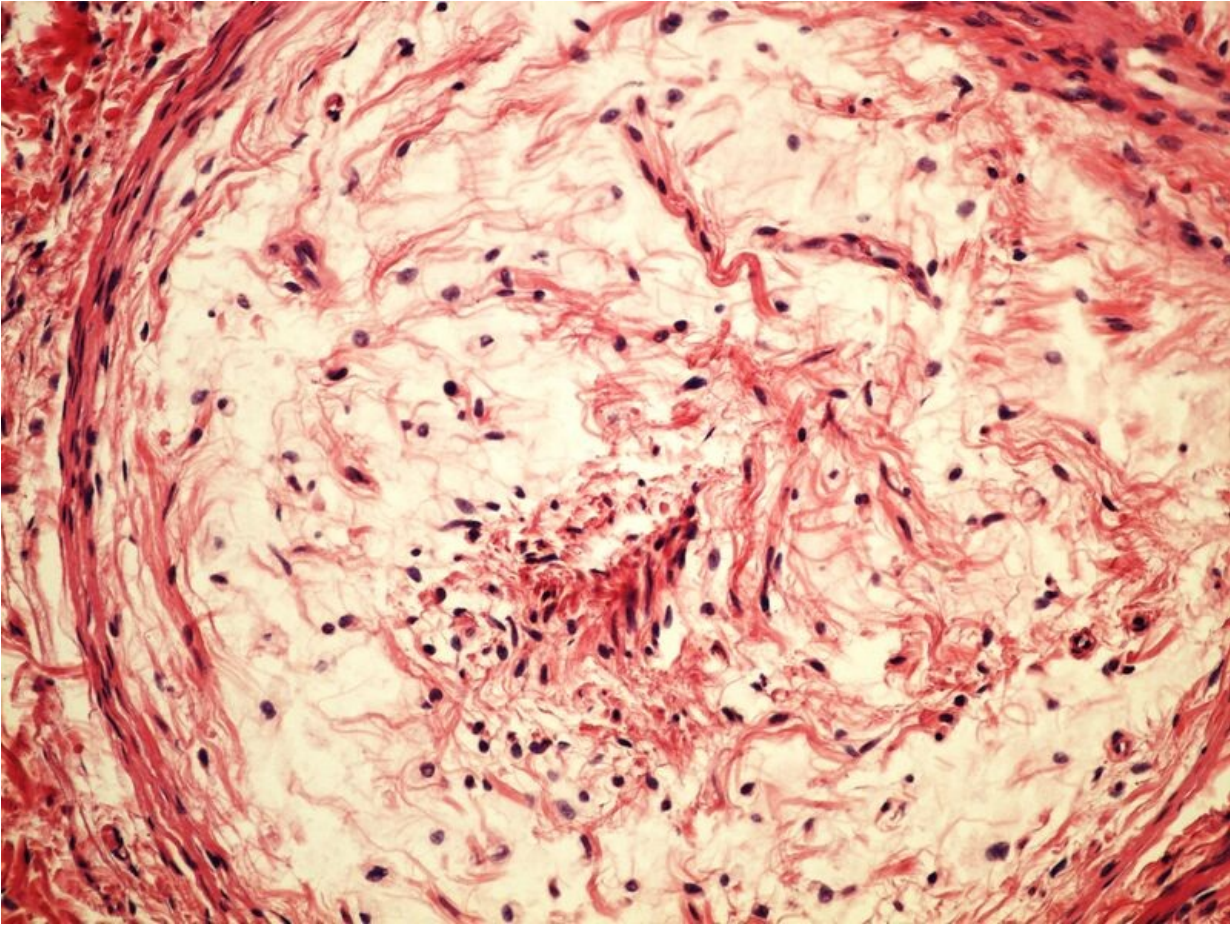


# File:Plexiform neurofibroma plexiformni neurofibrom 20x.jpg



Size of this preview: 800 × 600 pixels.

Original file (2,560 × 1,920 pixels, file size: 2.84 MB, MIME type: image/jpeg)

## Summary

### Description

Write a description here

### Author

Author's name and surname

### Source

Source web address or "own work"

### Date

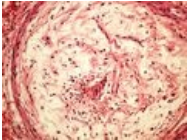
Date

## Licensing

 Creative Commons Attribution 4.0 Unported (<http://creativecommons.org/licenses/by/4.0/deed.en>)

## File history

Click on a date/time to view the file as it appeared at that time.

	Date/Time	Thumbnail	Dimensions	User	Comment
current	17:24, 9 May 2023		2,560 × 1,920 (2.84 MB)	TomasBarta (talk   contribs)	{{File  description = Write a description here  author = Author's name and surname  source = Source web address or "own work"  date = Date }}

You cannot overwrite this file.

## File usage

The following 3 pages use this file:

- Modul OZPP - Practice number 12
- Module GFPP - Practice no. 12
- Module General basics of pathology and pathophysiology - Overview of preparations

## Metadata

This file contains additional information, probably added from the digital camera or scanner used to create or digitize it.

If the file has been modified from its original state, some details may not fully reflect the modified file.