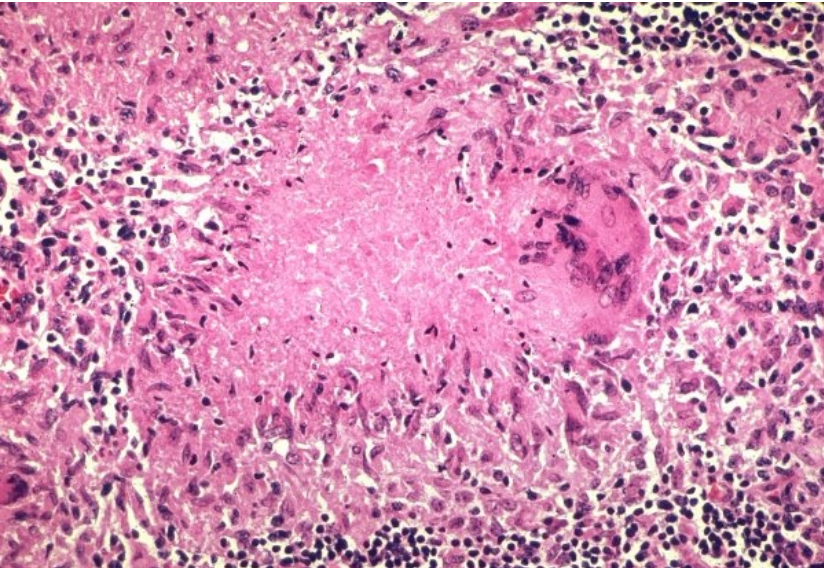


# File:Granuloma necrotizing87large.jpg



No higher resolution available.

Granuloma\_necrotizing87large.jpg (600 × 413 pixels, file size: 112 KB, MIME type: image/jpeg)

 [Open in Media Viewer](#) 

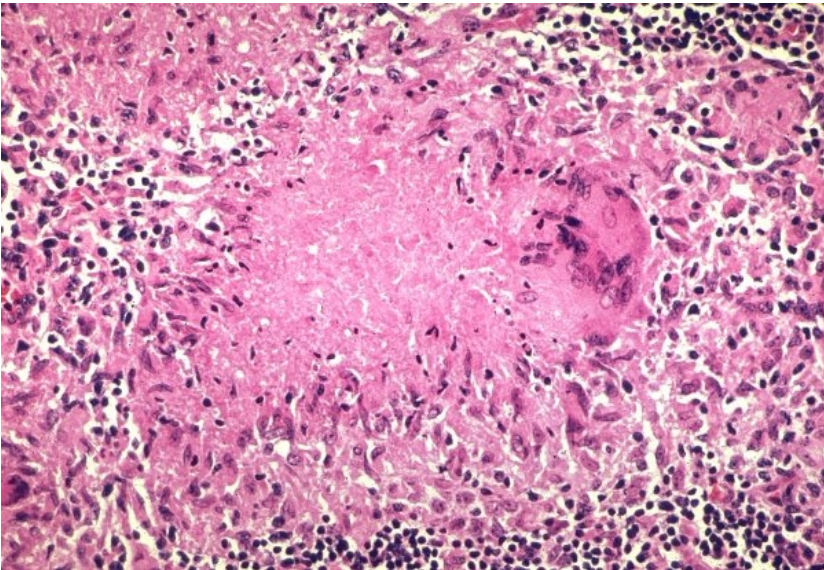
## Description

Necrotizing granuloma, TBC

## Author

Yale Rosen, M.D.

## Source



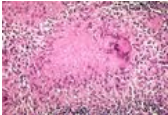
Date

## Licensing

Creative Commons NonCommercial-NoDerivs 3.0 Unported (CC BY-NC-ND 3.0) (<http://creativecommons.org/licenses/by-nc-nd/3.0/>)

## File history

Click on a date/time to view the file as it appeared at that time.

	Date/Time	Thumbnail	Dimensions	User	Comment
current	12:42, 3 April 2012		600 × 413 (112 KB)	Misa R (talk   contribs)	{ {File  description = Necrotizing granuloma, TBC  source = http://granuloma.homestead.com/files/granuloma_necrotizing87large.jpg  date =  author = Yale Rosen, M.D.  license = { {cc by-nd 3.0 cz}} } } Category:Pathology Category:Images

You cannot overwrite this file.

## File usage

The following page uses this file:

- Granuloma

## Metadata

This file contains additional information, probably added from the digital camera or scanner used to create or digitize it.

If the file has been modified from its original state, some details may not fully reflect the modified file.