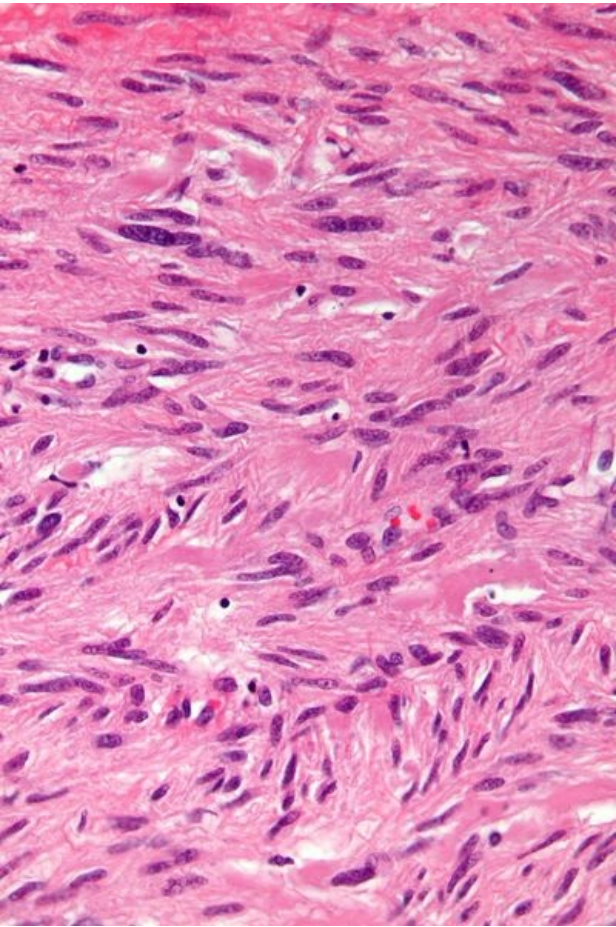


File:Gastrointestinal stromal tumour - very high mag.jpg



Size of this preview: 400 × 600 pixels.

Original file (2,848 × 4,272 pixels, file size: 5.42 MB, MIME type: image/jpeg)

 **Open in Media Viewer** 

Summary

Description
Write a description here

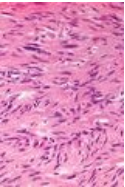
Author
Author's name and surname

Source
Source web address or "own work"

Date
Date

File history

Click on a date/time to view the file as it appeared at that time.

	Date/Time	Thumbnail	Dimensions	User	Comment
current	23:53, 29 November 2021		2,848 × 4,272 (5.42 MB)	Aly salam (talk contribs)	{ {File description = Write a description here author = Author's name and surname source = Source web address or "own work" date = Date } }

You cannot overwrite this file.

File usage

The following file is a duplicate of this file (more details):

- File:Gastrointestinal stromal tumour - very high mag.jpg from Wikimedia Commons

The following 3 pages use this file:

- Gastrointestinal stromal tumor
- Gastrointestinal stromal tumor/PGS
- Gastrointestinal stromal tumor / PGS

Metadata

This file contains additional information, probably added from the digital camera or scanner used to create or digitize it.

If the file has been modified from its original state, some details may not fully reflect the modified file.

Camera manufacturer	Canon
Camera model	Canon EOS DIGITAL REBEL XSi
Exposure time	1/50 sec (0.02)
F Number	f/0
ISO speed rating	320
Date and time of data generation	10:18, 19 April 2011
Lens focal length	0 mm