

File:Embolie retrográdní.png

retrográdní embolie

PODMÍNKA: zvýšení intrathorakálního tlaku

embolus v játrech (skrz vv. hepaticae)

hluboká žilní trombóza

Size of this preview: 600 × 600 pixels.

Original file (1,024 × 1,024 pixels, file size: 84 KB, MIME type: image/png)

Summary

Description

Diagram of the formation of retrograde embolism (from VCI through vv. hepaticae to the liver; the condition is an increase in intrathoracic pressure, e.g. coughing or abdominal compression)

Author

Icewalker

Source

own work

Date

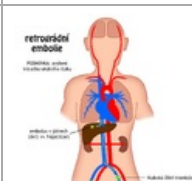
2011-03-15

Licensing

 Creative Commons Attribution 4.0 Unported (<http://creativecommons.org/licenses/by/4.0/deed.en>)

File history

Click on a date/time to view the file as it appeared at that time.

	Date/Time	Thumbnail	Dimensions	User	Comment
current	23:44, 31 March 2023		1,024 × 1,024 (84 KB)	JowelJ (talk contribs)	{{File description = Diagram of the formation of retrograde embolism (from VCI through vv. hepaticae to the liver; the condition is an increase in intrathoracic pressure, e.g. coughing or abdominal compression) author = Icewalker source = own work date = 2011-03-15 }}

You cannot overwrite this file.

File usage

The following page uses this file:

- Embolism

Metadata

This file contains additional information, probably added from the digital camera or scanner used to create or digitize it.

If the file has been modified from its original state, some details may not fully reflect the modified file.