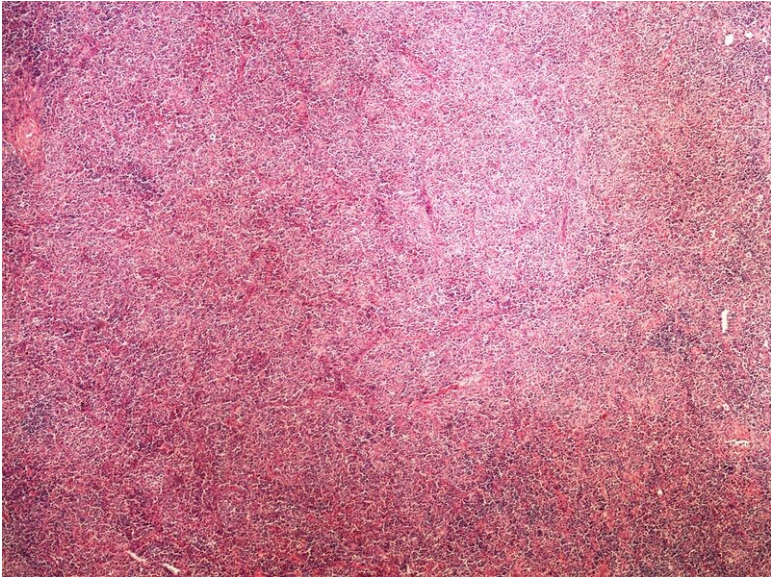


**File:Classic Hodgkin lymphomad mixed cellularity klasicky Hodgkinuv lymfom smisena celularita 4x.jpgg**



Size of this preview: 800 x 600 pixels.

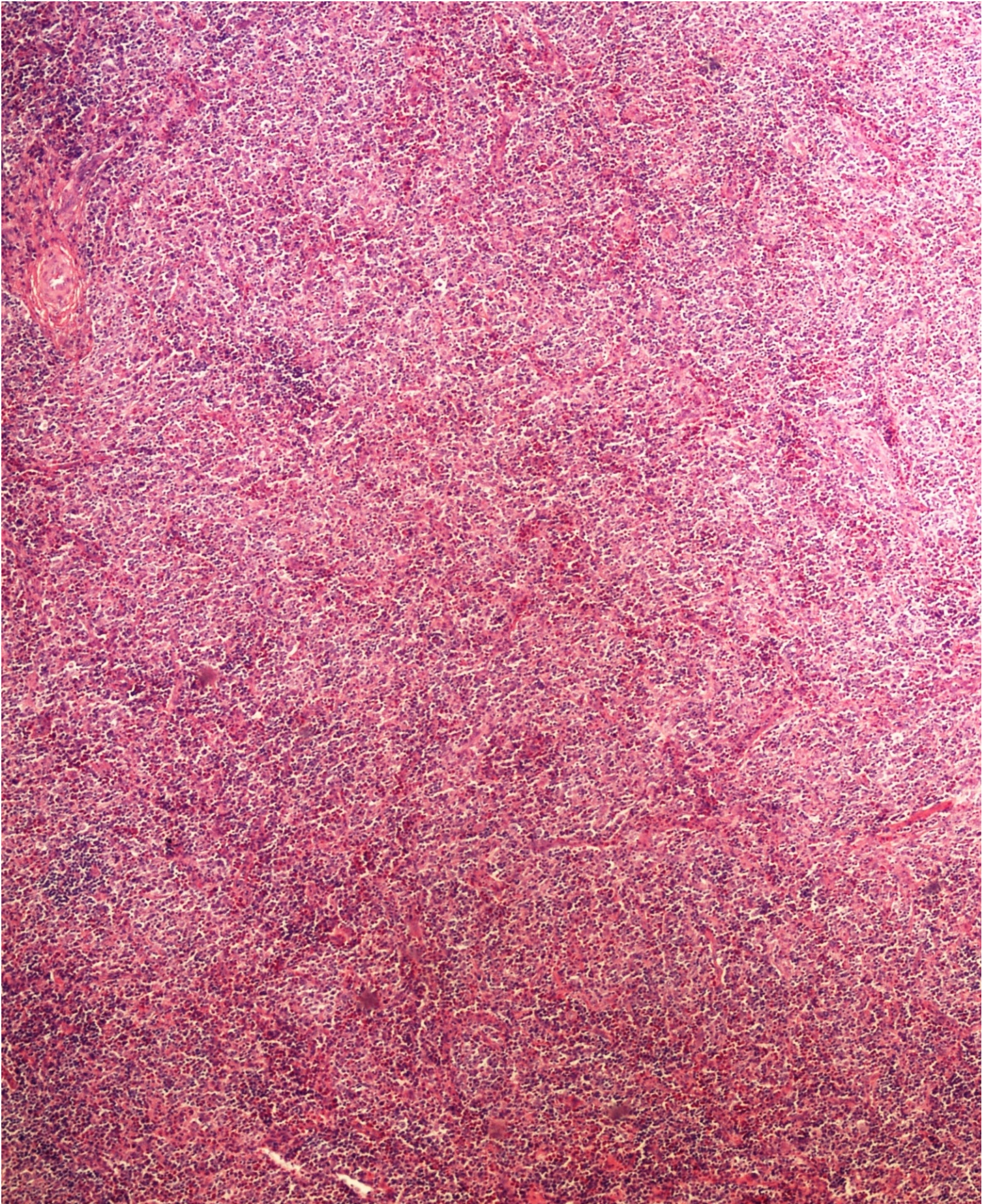
Original file (2,560 × 1,920 pixels, file size: 4.5 MB, MIME type: image/jpeg)

 [Open in Media Viewer](#) 

**Summary**

**Summary**





Licensing

Licensing

File history

Click on a date/time to view the file as it appeared at that time.

|         | Date/Time          | Thumbnail | Dimensions             | User                     | Comment  |
|---------|--------------------|-----------|------------------------|--------------------------|--|
| current | 05:48, 22 May 2023 |           | 2,560 × 1,920 (4.5 MB) | Rynard (talk   contribs) | {{File:Classic Hodgkin lymphomad mixed cellularity klasicky Hodgkinuv lymfom smisena celularita 4x.jpg  author = Patologie3LF  source =https://www.wikiskripta.eu/w/Soubor:Classic_Hodgkin_lymphomad_mixed_cellularity_klasicky_Hodgkinuv_lymfom_smisena_celularita_4x.jpg  date = 20/05/2023 }} |



You cannot overwrite this file.

## File usage

The following 3 pages use this file:

- Module GFPP - Practice no. 14
- Module General basics of pathology and pathophysiology - Overview of preparations
- File:Classic Hodgkin lymphomad mixed cellularity klasicky Hodgkinuv lymfom smisena celularita 4x.jpg

## Metadata

This file contains additional information, probably added from the digital camera or scanner used to create or digitize it.

If the file has been modified from its original state, some details may not fully reflect the modified file.