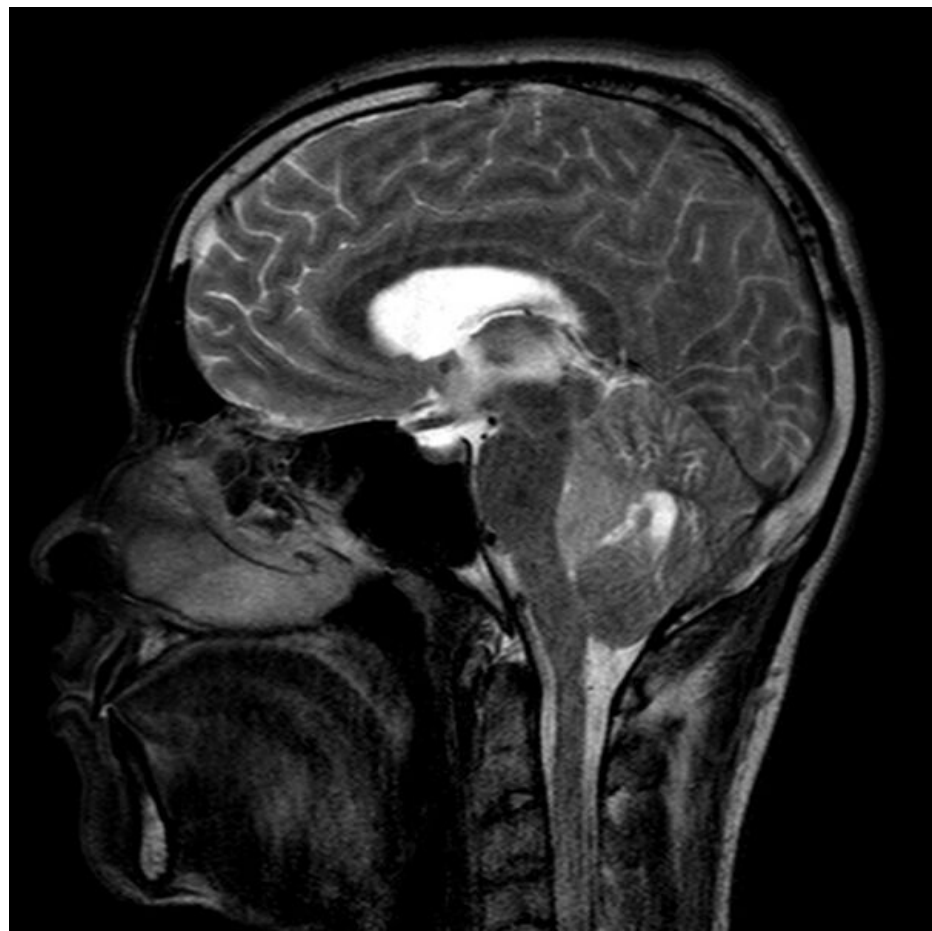


File:Anaplas mri.jpg



Size of this preview: 600 x 600 pixels.

Original file (630 × 630 pixels, file size: 92 KB, MIME type: image/jpeg)

Summary

Description

Write a description here

Author

Author's name and surname

Source

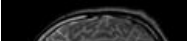
Source web address or "own work"

Date _____

Date

File history

Click on a date/time to view the file as it appeared at that time.

	Date/Time	Thumbnail	Dimensions	User	Comment
current	22:48, 18 February 2022		630 × 630 (92 KB)	LauraKuz (talk contribs)	{{File description = Write a description here author = Author's name and surname source = Source web address or "own work" date = Date }}

You cannot overwrite this file.

File usage

The following 2 pages use this file:

- Ependymoma

- Tumors of cerebellum and IV. ventricle in adults