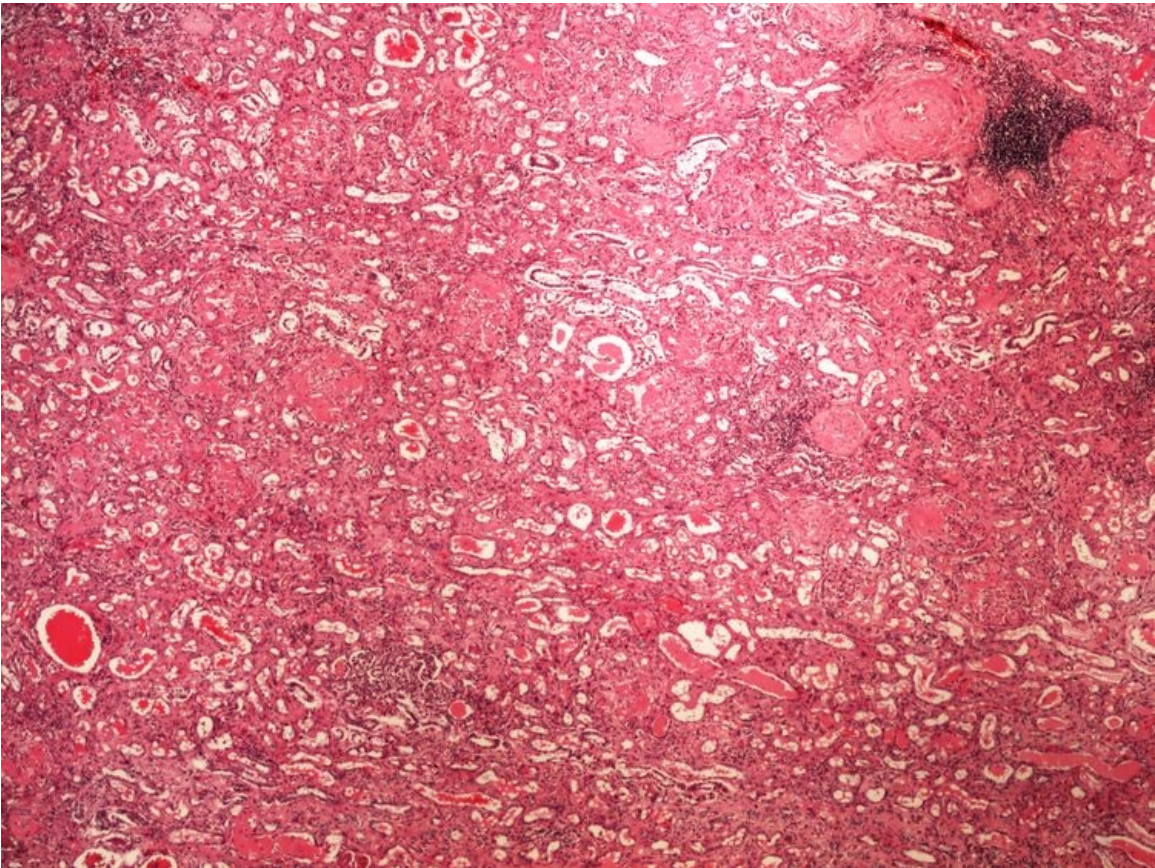


# File:Amyloidosis kidney amyloidoza ledviny HE 4x.jpg



No higher resolution available.

Amyloidosis\_kidney\_amyloidoza\_ledviny\_HE\_4x.jpg (750 × 563 pixels, file size: 168 KB, MIME type: image/jpeg)

Amyloidosis kidney amyloidoza ledviny HE 4x

## File history

Click on a date/time to view the file as it appeared at that time.

	Date/Time	Thumbnail	Dimensions	User	Comment
current	15:54, 31 March 2023		750 × 563 (168 KB)	MrABC (talk   contribs)	

You cannot overwrite this file.

## File usage

The following 3 pages use this file:

- Module GFPP - Practice no. 3
- Module General basics of pathology and pathophysiology - Overview of preparations
- OZPP module - Practicum No. 3

## Metadata

This file contains additional information, probably added from the digital camera or scanner used to create or digitize it.

If the file has been modified from its original state, some details may not fully reflect the modified file.

