

Femoral Triangle

English: *Femoral triangle*

Latin: *Trigonum femorale*



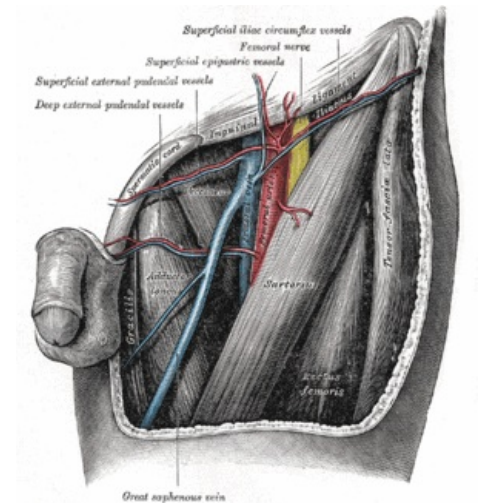
The **femoral triangle** (**Scarpa's triangle**, lat. *trigonum femorale*) is bounded by:

- (superiorly) the inguinal ligament
- (medially) the medial border of adductor longus
- (laterally) the medial border of sartorius
- Its floor is formed by the iliopsoas and pectineus.
- Its roof is formed by the fascia lata.

Links

Bibliography

- PETROVICKY, Pavel, et al. *Anatomie s topografií a klinickými aplikacemi : Sv. 1, Pohybové ústrojí*. 1. edition. Martin : Osveta, 2001. 463 pp. ISBN 80-8063-046-1.



Femoral triangle