

Extensor hallucis brevis muscle

Beginning: dorsal side of the calcaneus, adjacent ligaments of the tarsus

Attachment: dorsal aponeurosis of the thumb

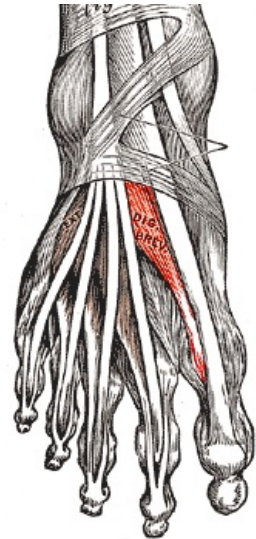
Innervation: nervus fibularis profundus (L₄-S₁)

Function: extension of the metatarsophalangeal and interphalangeal joints of the thumb

Links

References

- ČIHÁK, Radomír. *Anatomie 1*. 2. edition. Grada, 2001. 497 pp. ISBN 80-7169-970-5.
- VIGUÉ, Jordi. *Atlas lidského těla*. 3. edition. Rebo, 2007. ISBN 978-80-7234-881-7.



Musculus extensor hallucis brevis