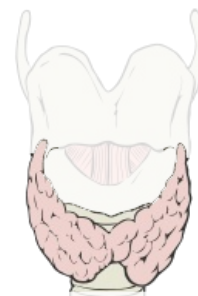

# Examination of the Thyroid Gland

## Thyroid gland (glandula thyroidea)

 For more information see *Thyroid gland*.

The thyroid gland is one of the endocrine glands. It consists of two lobes, which are placed at the sides of the larynx and the upper part of the trachea. Both lobes are connected by isthmus. Under normal circumstances, the lobe length is **5-8 cm**, the width **2-4 cm** and the lobe thickness **1.5-2.5 cm**. The isthmus is about **1.5 cm** long. The whole thyroid gland weighs in the range of **30-40 g**. The basic functional unit of the thyroid gland is the **follicles**. They are closed bags of irregular, spherical shape. The wall of the vesicles is formed by a single layer of epithelial cells. The follicles are filled with **colloid**. The main component of the colloid is **thyroglobulin**, which contains the main thyroid hormones **thyroxine** and **triiodothyronine**. The third thyroid hormone is **calcitonin**. It is formed by parafollicular cells stored in small groups in the interstitial ligament between the follicles.



## Thyroid hormones

The thyroid gland plays a major role in controlling the metabolism of human body. It is unique in the sense that its function (production of **triiodothyronine: T3**, reversed **triiodothyronine: rT3** and **thyroxine**) is dependent on the supply of iodine in food or water. In the blood, T3 and T4 are bound to globulin and prealbumin and then penetrate the plasma membrane into the cells. However, up to 90% of thyroxine is converted to triiodothyronine before binding to the cytosolic receptor. The hormone-receptor complex is then transported to the nucleus, where it affects the synthesis of mRNA and thus the synthesis of various types of proteins. Parafollicular cells are involved in the regulation of calcium and phosphatemia by producing calcitonin.

### Basic effects of hormones

1. **Calorigenic effect** – increase of the metabolic activity of cells – higher oxygen consumption, higher heat production,
2. **carbohydrate metabolism** – increase of glucose uptake by cells, glycolysis, lipid metabolism,
3. **positive chronotropic and inotropic effect** on circulatory system,
4. **increase of the activity of the central nervous system** (increased irritability, accelerated reflex response),
5. **affecting development and differentiation** (T4 deficiency during development leads to disorders of protein synthesis, disorders of growth and differentiation of nerve cells, myelin is impaired, which can result in irreversible damage to somatic and mental development).

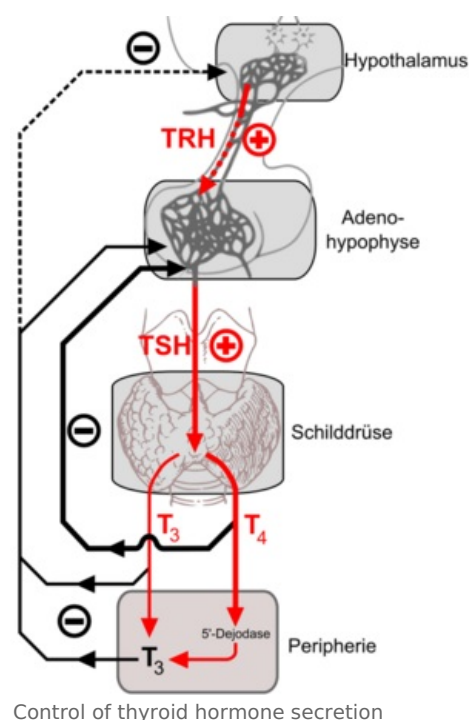
The secretion of thyroid hormones is regulated along the Hypothalamus-adenohypophysis-thyroid gland axis.

Thyroid problems are not uncommon, they affect women more often. Hormone production may be excessive (**hyperthyroidism**) or insufficient (**hypothyroidism**), the volume of the gland may be increased, which may cause oppression of vital structures in the neck, or the formation of nodules, behind which the tumor growth may hide.

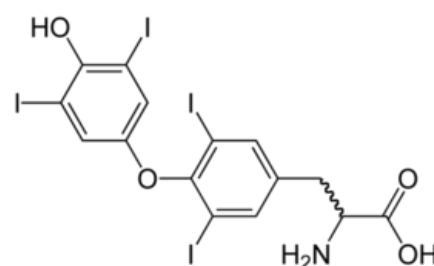
Diagnosis of thyroid disease is a process that can involve many procedures, including clinical examinations, blood tests, various imaging methods, biopsy, and more. The basis is, of course, an anamnestic examination. In addition to the current problems, important indicators include the data on thyroid diseases in the family (the family incidence is present in almost half of the cases of thyroid diseases), the places, where the patient lived (due to possible iodine deficiency), the medication (some can cause thyroid disorders), and the history of past diseases, injuries and operations (thyroid diseases can initiate).

## Clinical examination

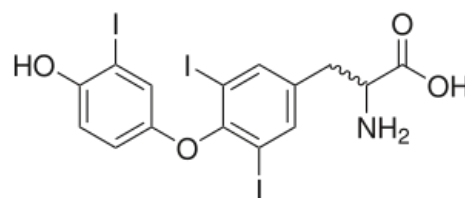
- **palpation** to detect an enlarged thyroid gland or a formation of bumps or nodules,



Control of thyroid hormone secretion



Thyroxine



Triiodothyronine

- **auscultation** revealing increased gland flow, pulse and blood pressure (tachycardia, bradycardia, arrhythmia, palpitations).

Other important factors:

- unusual weight loss or weight gain,
- evaluation of the appearance of eyes – protrusion of the eyes, retraction of the upper eyelids, eyes wide open,
- color of skin (yellowing),
- possible evaluation of the occurrence of tremor in hyperkinetic movements.

## Blood tests

Reference values of TSH (mIU/L)

values of TSH (mIU/L)	diagnostic statement
to 0.1	hyperthyroidism with a suppressed pituitary-thyroid regulatory axis
0.1–0.3	lower limit of hyperthyroidism
0.3–3.5	euthyroid range
3.5 – 10	hypothyroidism threshold, iodine utilization disorders
from 10	hypothyroidism

- **Free thyroxine = free T4 (FT4)** – thyroxine, not bound to protein transporters and immediately available to cells, is usually elevated in hyperthyroidism and decreased in hypothyroidism.
- **Total thyroxine = total T4** – the total amount of thyroxine in the blood, the evaluation of increased or decreased values is the same as the free thyroxine, but the result of this test may be affected by, for example, pregnancy or the use of hormonal contraception.
- **Total triiodothyronine = total T3, free triiodothyronine = free T3 (FT3)** – the same evaluation as in the previous tests, again the level of free T3 is a more accurate indicator.
- **Thyroglobulin Tg** – undetectable or in minimal amount in a healthy person, increased in thyroiditis, or thyroid tumors, in this case Tg levels are also used as evaluation of the success of the treatment.

## Iodine uptake scan (RAI-U)

A test that clarifies how well the gland absorbs and processes iodine (iodine uptake sensing). The patient is orally administered a substance with a radioactive isotope iodine (**iodine 123**) and a special device monitors the extent to which and where the element is processed in the thyroid gland. This imaging method identifies the so-called **"hot"** and **"cold"** **nodules** in the gland.

- A malignant tumor is rarely indicated by the **"hot"** nodules.
- **"Cold"** nodules (which don't show activity when scanned) tend to be more treacherous. It shows the size of the gland before an operation of the malignant tumor, and after the operation, it reveals the tumor's unoperated part. It can locate thyroid tissue in other places than the neck (**ectopy**).

## US, CT, MRI examination

It can detect nodules in the gland hidden during palpation, it is used to evaluate the nodule and spread. It distinguishes a cyst filled with fluid from a solid. However, it does not distinguish a benign nodule from a malignant one. With the help of ultrasound, we can measure the size and estimate the volume of the gland.

## Fine needle biopsy

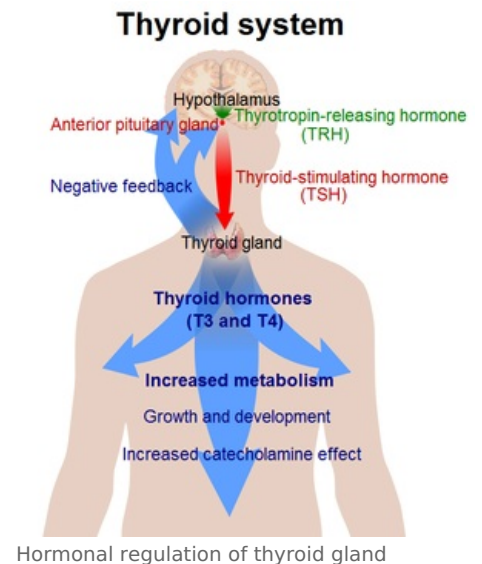
 For more information see *Biopsy*.

A tissue sample of the thyroid gland for microscopic examination is taken by a puncture with a thin needle.

## Links

### Related articles

- Thyroid disease
- Examination for thyroid diseases
- Radionuclide examinations of the thyroid gland
- Calcitonin



- Parathormon

## Bibliography

- ČIHÁK, R. *Anatomie 2*. 1. edition. 2002. pp. 470. ISBN 80-247-0143-X.
- MARTINÍK, K. *Základní algoritmus detekce poruch štítné žlázy v denní praxi lékaře* [online]. The last revision 2007, [cit. 6. 4. 2009]. <<http://www.profmartinik.cz/wp-content/soubory/stitna-zlaza-detekce-poruchy.pdf>>.

## External links

- [http://www.pharmanews.cz/2005\\_05/stitna.htm](http://www.pharmanews.cz/2005_05/stitna.htm)
- <https://www.verywellhealth.com/thyroid-4014636>
- [http://ciselniky.dasta.mzcr.cz/CD\\_DS4/hypertext/PIAAP.htm](http://ciselniky.dasta.mzcr.cz/CD_DS4/hypertext/PIAAP.htm)
- [http://www.pharmanews.cz/2005\\_05/stitna.htm](http://www.pharmanews.cz/2005_05/stitna.htm)