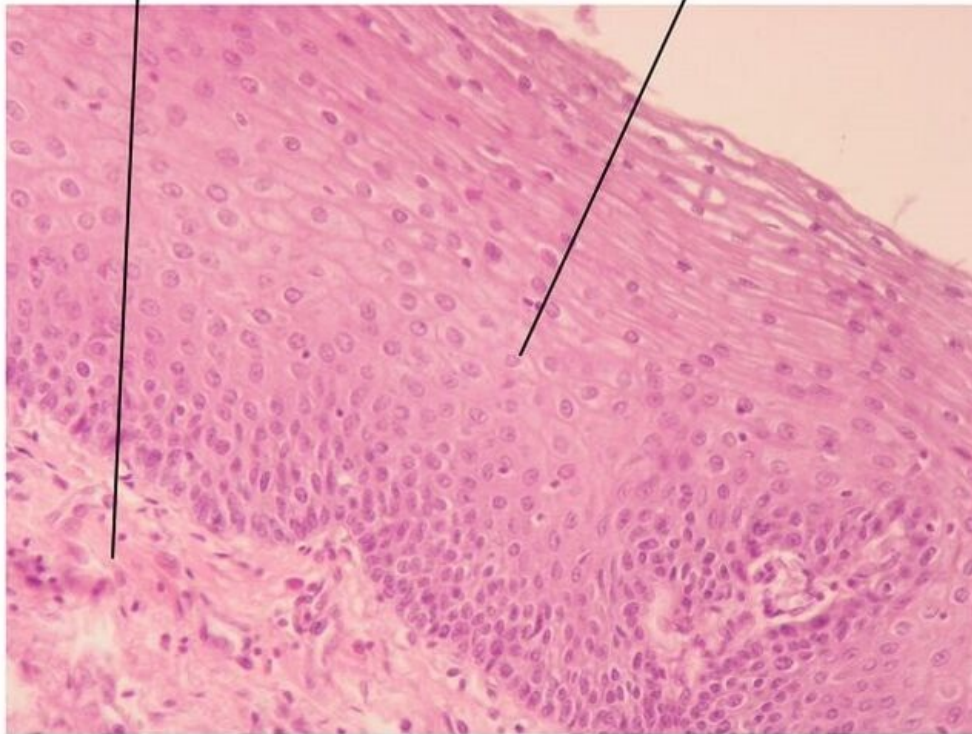


Esophagus, detail (image)

lamina propria mucosae

non-keratinized stratified squamous epithelium



Esophagus - H&E stain

Esophagus – detail