

# Erythropoiesis

**Erythropoiesis** describes a process in which red blood cells develop in the islets bone marrow from multiploid **myeloid progenitor cells** (hematopoietic stem cells). During the maturation of erythrocytes, cell volume decreases, hemoglobin accumulates, and finally the nucleus is eliminated. The presence of the hormone erythropoietin, iron, vitamin B<sub>12</sub> and interleukin (IL3, IL4) is essential for development. . Dividing 1 hematopoietic stem cell produces  $2^{11}$  erythrocytes. Every minute,  $2 \times 10^6$  are created at the same time. Development takes approximately **7 days**.

## Differentiation

 For more information see *Hematopoiesis*.

Precursor cells for erythrocytes (proerythroblasts) develop from a hematopoietic stem cell, which is a common basis for the development of all blood elements, ie megakaryocytes, granulocytes and monocytes.

### Proerythroblast

A round cell (**14 -20 µm** ) with a round core that fills most of its volume, located in the center of the cell. It usually contains 1-2 nuclei and lumpy chromatin. Characteristic is perinuclear clearance and basophilia due to the presence of polyribosomes. The cytoplasm does not contain granules and is poor in organelles (located in the perinuclear brightening). Iron (in the form of the molecule ferritin) accumulates in structures called **siderosomes** and is important for future hemoglobin synthesis. Its division produces 2 **basophilic erythroblasts**.

### Basophilic erythroblast

The basophilous erythroblast is a spherical cell (**12 -16 µm** ). Its core is large, spherical and located **eccentrically**. Chromatin is more condensed than in the case of proerythroblast, nucleoli are not clear. Cytoplasm basophilia is more intense than in the previous stage, due to an increase in the number of polyribosomes due to the onset of **hemoglobin synthesis**.

### Polychromatophilic erythroblast

At this stage of development, the cytoplasm stains change from basophilic to **amphiphilic** (stained with both acidic and basic dyes) due to increasing hemoglobin concentration. The nucleus shrinks due to chromatin thickening, as well as the cell itself (**12 -14 µm**). This is the last stage of erythrocyte development, when division can occur.

### Orthochromatic erythroblast

Round to oval cell (**8-10 µm**) with a small, highly condensed (**pyknotic**) nucleus. This, together with the other organelles, is stored eccentrically. The cytoplasm is clearly eosinophilic due to hemoglobin concentration. The formation of protrusions from the cytoplasm causes the nucleus to be strangled ("extruded") by the cytoskeleton, which is then phagocytosed by macrophages. **Without a kernel, the cell cannot divide.**


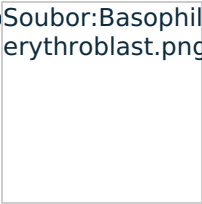
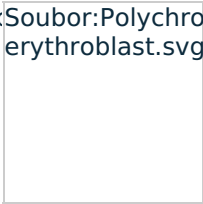
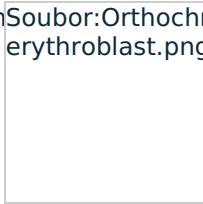
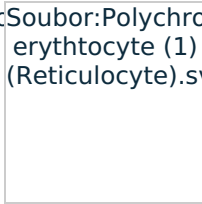
### Reticulocytes

These are non-nuclear blood elements (**8 µm**) in a shape resembling a **biconcave disc**. In the cytoplasm, we find the remnants of polyribosomes stained with **brilliant crescent blue**. In the bloodstream, they represent 1-2% of the total number of red blood cells. This proportion may increase with increased erythrocyte losses - such as bleeding.

### Erythrocyte

 For more information see *Erythrocytes*.

## Scheme of cells

Soubor:Proerythroblast.png	Soubor:Basophilic erythroblast.png	Soubor:Polychromatic erythroblast.svg	Soubor:Orthochromatic erythroblast.png	Soubor:Polychromatic erythrocyte (1) (Reticulocyte).svg
				
Proerythroblast	Basophilic erythroblast	Polychromatic erythroblast	Orthochromatic erythroblast	Reticulocyte

Links

Related articles

- Hematopoiesis
- Blood ■ Erythrocyte ■ Megakaryocyte ■ Granulocytes ■ Monocyte
- Mitosis
- Staining in light microscopy