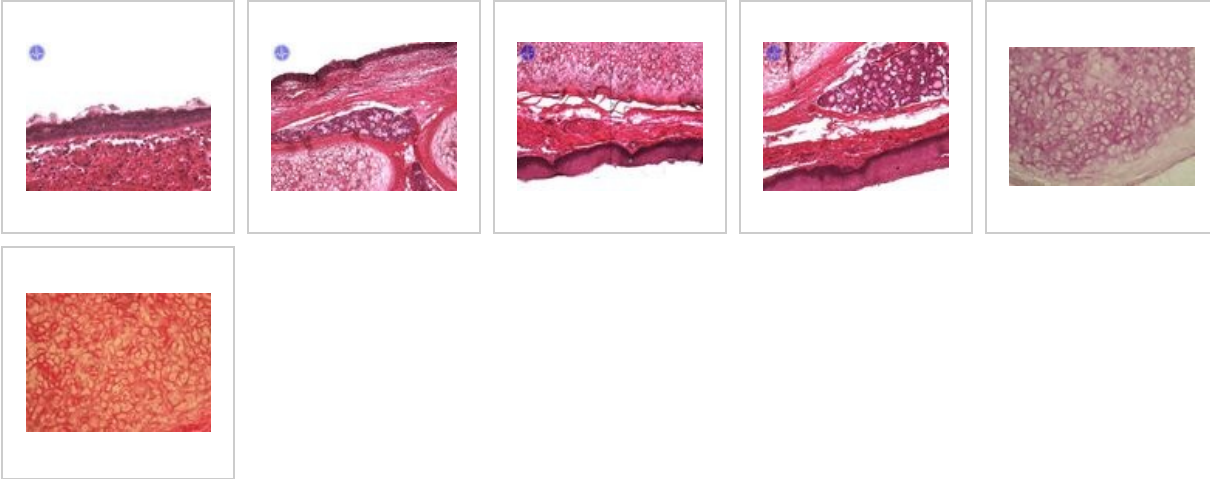


Epiglottis (SFLT)



Respiratory tract

- Epiglottis (SFLT)
- Larynx (SFLT)
- Trachea (SFLT)
- Bronchus segmentalis (SFLT)
- Lung (SFLT)
- Fetal lung (SFLT)

Links

- Histological atlas (3. LF UK)