

# Endometriosis

Endometriosis<sup>[1][2][3]</sup> is a pathological localization of the endometrium elsewhere than in the uterine cavity. Any organ can be affected (perhaps with the exception of the spleen and heart), the most common being pelvic endometriosis. These are cysts filled with dark brown fluid ("chocolate cysts"), non-cystic endometrial tissue, and adhesions.

## Epidemiology

One fifth of patients who visit a gynecological clinic suffer from endometriosis . In autopsy material (enucleated myomas, hysterectomies, etc.), ectopically deposited endometrial tissue is found in 90% .

Risk factors are:

- obstructive and congenital abnormalities of the genital tract – related to the reflux of menstrual blood into the fallopian tubes and peritoneal cavity; with the proper functioning of the immune system, minor reflux does not cause problems, but pathologically, endometrial tissue can be attached ectopically,
- short menstrual cycle (27 days or less),
- late pregnancy and low parity (related to increasing incidence due to the trend of higher socioeconomic status).

## Anatomical distribution

The most common localization of endometriosis is generally pelvic, more specifically on the sacrouterine ligaments (60%), followed by the ovaries. However, it can occur anywhere in the body (cases of occurrence in the conjunctival sac, brain, etc. are described).

We distinguish:

- endometriosis genitalis , i.e.:
  - *endometriosis genitalis interna uteri et tubae* – endometriosis affecting the myometrium or fallopian tubes,
  - *endometriosis genitalis externa* – involvement of sacrouterine ligaments or ovaries,
- endometriosis extragenitalis – all other locations.

## Symptomatology

The symptomatology of endometriosis is diametrically different depending on the location. The affected organ largely determines the nature of the symptoms. The intensity of symptomatology does not correlate at all with the degree of endometriosis. A small finding can cause great difficulties, and a very advanced finding can be asymptomatic . Symptoms include:

- sterility – when the ovaries are affected,
- pain - in the case of involvement of the sacrouterine ligaments, rectovaginal septum or myometrium.

Ectopic endometrial tissue undergoes the same cyclical changes as normally located tissue: proliferation, secretion and bleeding. During bleeding, inflammation occurs locally, which hurts in connection with the menstrual cycle - central cyclic pelvic pain . Adhesions can subsequently form that hurt permanently, the nature of the pain then depends on the affected organ:

- dysmenorrhea – a synonym for central cyclic pelvic pain ,
- dyspareunia – pain during intercourse,
- dyschesia – pain during defecation (adhesions with the intestine),
- pelipathia (sometimes also the form "*pelvipathia*" or "*pelvialgia*") - non-cyclic pelvic pain (at first, cyclic inflammation develops into permanent adhesions with permanent pain).

## Diagnostics

Cyclic pain is a key finding in the anamnesis . A non-specific finding is found during the physical examination. Ultrasound examination is very beneficial and the gold standard in the diagnosis of endometriosis providing confirmation of the diagnosis is laparoscopy .

## Differential diagnosis

Patients with a history of chronic adnexitis and ATB treatment often come to the outpatient clinic. There are cases where it is not chronic adnexitis, but precisely endometriosis, and the subjective improvement is not related to treatment with deoxymycoin, but to the course of the menstrual cycle. It is necessary to investigate anamnesticly an episode of acute pelvic inflammation, from which "real" chronic adnexitis could develop, or to consider whether it is precisely endometriosis.

The differential diagnosis of endometriosis includes:

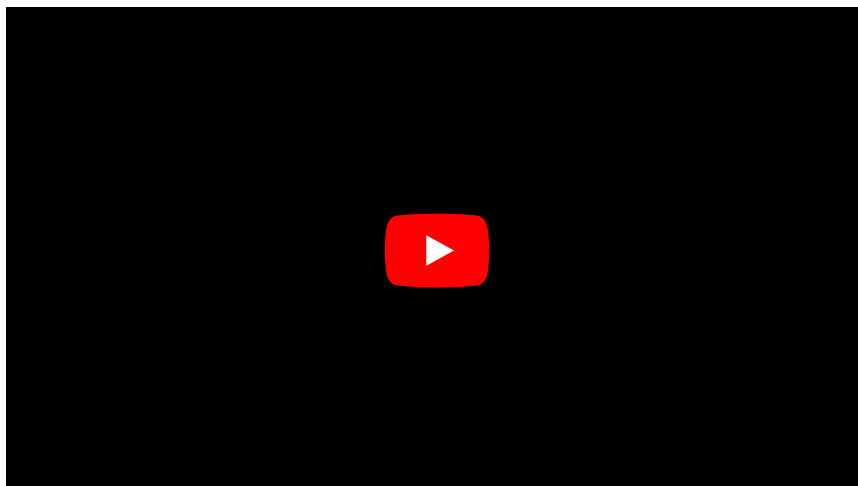
- chronic pelvic inflammation,
- ovarian cyst (and other solid adnexal pathologies),
- uterine myomatosis.

## Therapy

Therapy can be either surgical , medicinal or combined . If the woman is no longer planning pregnancy, the most effective therapy is a surgical radical approach: bilateral ovariectomy (mostly in the form of hysterectomy with bilateral adnexectomy). Otherwise, a conservative surgical approach is laparoscopic treatment of endometriosis foci (enucleation of cysts, electrocoagulation of foci, laser treatment). Ovulation blockade is used in medical treatment - progestins (medroxyprogesterone acetate), estrogen-gestagen treatment ( hormonal contraception ), GnRH analogues (goserelin, buserelin, triptorelin).

Hormonal contraception is also often the first-choice method.

## Summary video



## Links

### Related Articles

- Endometrium
- Uterine myoma

### External links

- Endometriosis (English Wikipedia article)
- Endometriosis

### References

1. , BCJM FAUSER and K DIEDRICH, et al. Contemporary genetic technologies and female reproduction. *Hum Reprod Update* [online] . 2011 Nov-Dec, vol. 17, no. 6, pp. 829-47, also available from < <https://www.ncbi.nlm.nih.gov/pmc/articles/PMC3191938/?tool=pubmed> >. ISSN 1355-4786 (print), 1460-2369.
2. ↑Jump up to:a b c d e f g CONE, David. *Gynecological endoscopy, endometriosis* [lecture on the subject Gynecology and Obstetrics pre-state internship, field of General Medicine, 1st Faculty of Medicine, Charles University in Prague]. Prague. 20/02/2014. Also available from < <https://el.lf1.cuni.cz/gpkuzel1a> >.
3. ↑ ROB, Lukáš, Alois MARTAN and Karel CITTEBART. *Gynecology*. 2nd edition. Prague: Galén, 2008. 390 pp. pp. 143-147. ISBN 978-80-7262-501-7 .
1. KUŽEL, David. *Gynekologická endoskopie, endometrióza* [přednáška k předmětu Gynekologie a porodnictví předstátnicová stáž, obor Všeobecné lékařství, 1. lékařská fakulta Univerzita Karlova v Praze]. Praha. 20.2.2014. Dostupné také z <<https://el.lf1.cuni.cz/gpkuzel1a>>.
2. ROB, Lukáš, Alois MARTAN a Karel CITTEBART. *Gynekologie*. 2. vydání. Praha : Galén, 2008. 390 s. s. 143-147. ISBN 978-80-7262-501-7.
3. B C J M FAUSER a K DIEDRICH, et al. Contemporary genetic technologies and female reproduction. *Hum Reprod Update* [online]. 2011 Nov-Dec, vol. 17, no. 6, s. 829-47, dostupné také z <<https://www.ncbi.nlm.nih.gov/pmc/articles/PMC3191938/?tool=pubmed>>. ISSN 1355-4786 (print), 1460-

