

# Electrical cardioversion

**Electrical cardioversion** is a procedure used to treat certain arrhythmias (especially atrial fibrillation and atrial flutter). In most cases, this is elective output performed on an outpatient basis.

## Indication

The electric version is classically performed for heart rhythm disorders that occur in the atria of the heart (so-called **supraventricular arrhythmias**). These are most often atrial fibrillation or flutter and other supraventricular tachyarrhythmias. In most cases, it is performed electively during short-term hospitalizations or on an outpatient basis. It is also urgently indicated in supraventricular tachyarrhythmias accompanied by hemodynamic instability, where it is assumed that the cause of this instability is the ongoing arrhythmia. However, these situations should always be carefully evaluated, including the possible risk of thromboembolism. Electrical cardioversion can also be performed in hemodynamically insignificant persistent monomorphic ventricular tachycardia.<sup>[1]</sup>

If we have a patient diagnosed with an arrhythmia, meant in this article mainly in the form of atrial fibrillation, we must evaluate several facts. In patients with atrial fibrillation, in addition to proper **anticoagulation**, we attempt **rhythm-control and rate-control**. In newly diagnosed supraventricular tachyarrhythmias, we first try to identify and adequately treat the underlying cause, which includes, among other things, testing for electrolyte levels, thyroid hormones and eliminating intoxication (eg digitalis). Next, we try to end (rhythm-control) or at least "slow down" (rate-control) the arrhythmia. One possibility is **pharmacological intervention**, eg by administering beta-blockers, propafenone, non-dihydropyridine type calcium channel blockers, adenosine or amiodarone depending on the type of arrhythmia.

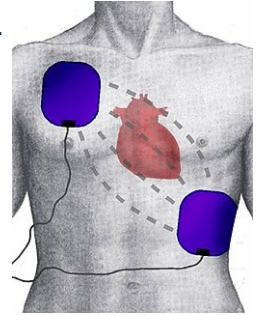
If this attempt fails or the arrhythmia recurs, electrical cardioversion should be considered. **In younger patients with the first documented occurrence of atrial fibrillation, it is preferred to perform electrical cardioversion first, which generally has the best results in the sinus rhythm version. If even this is unsuccessful, usually after several attempts, Radiofrequency catheter ablation (RFA) may be considered.**

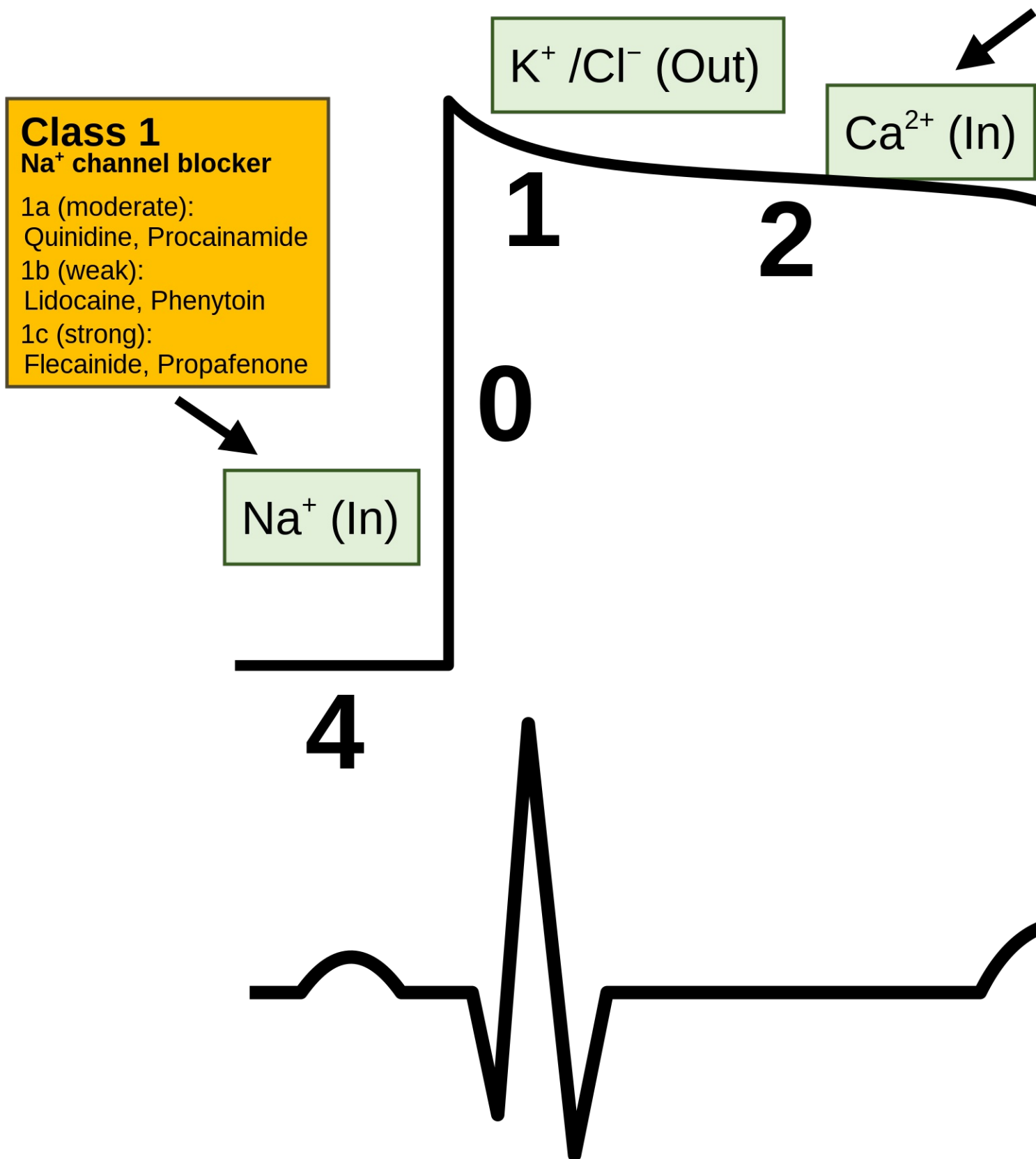
With all these procedures, we try to achieve rhythm control (rhythm-control). Such an approach can also be considered in patients with long-lasting supraventricular tachyarrhythmias, which is markedly symptomatic. If sinus rhythm maintenance is not achievable in patients or they are contraindicated to perform electrical or pharmacological versions, we try to at least rate-control through antiarrhythmics, beta-blockers or pacing.

Electrical cardioversion **is not performed in patients with an intracardiac thrombus finding** (see below) and in asymptomatic or minimally symptomatic highly polymorbid patients, in whom the risk of surgery and subsequent therapy to maintain sinus rhythm far outweighs the potential benefits. Furthermore, we do not perform the version in patients with contraindications for anticoagulant therapy, in patients who have repeatedly failed attempts to control rhythm (i.e permanent atrial fibrillation) and in patients with parameters that predict cardioversion or RFA failure, such as severe left atrial dilatation or significant mitral insufficiency.

## Principle

Electrical cardioversion is performed by a cardiologist with the assistance of an anesthesiologist. The patient is placed in a special bed (coronary unit, ICU, catheterization laboratory), which allows **monitoring of basic vital functions** (blood pressure, respiratory rate, heart rate). The anesthetist puts the patient under short-term general anesthesia (etomidate or propofol i.v. + fentanyl or alfentanil).





It is used for self-cardioversion **defibrillator**. The cardiologist applies two electrodes smeared with a conductive gel to the patient's chest (very often hands-free electrodes are used today). The so-called **anterolateral position** – one electrode is placed in 2. – 3. intercostal space parasternally to the right and the other to the tip of the heart (anteroposterior position is used in patients who have an implanted pacemaker or defibrillator)<sup>[1]</sup>. It is applied over the chest surface **biphasic discharge synchronized with wave R** on initial energy (depending on the type of arrhythmia) 100–150 J in order to interrupt the given arrhythmia and restore the physiological heart rhythm <sup>[2]</sup>. We are then talking about the so-called **synchronized cardioversion**.

The pathophysiological nature of arrhythmias, which we try to end with electrical cardioversion, is the presence of **re-entry circuits**. By administering an energy shock in the form of electrocardiography, **we depolarize all the cells of the heart muscle and all the cardiac conductive tissue** at the same time, **including pathological re-entry circuits**. **This is followed by a refractory phase, which should lead to disruption of re-entry circuits, which will give the sinoatrial node a chance to "take control" again.** Synchronization of the shock with the R wave on the ECG is the prevention of malignant arrhythmias. **If a shock is applied during myocardial repolarization (i.e the T wave), there is a high probability of the development of ventricular tachyarrhythmias (this is a relative, vulnerable, refractory phase of the cardiac cycle).** **If the shock is not synchronized, we speak of defibrillation, which is used only for hemodynamically severe arrhythmias (ventricular tachycardia without pulse or ventricular fibrillation).**

To improve electrical cardioversion results in maintaining sinus rhythm, patients sometimes use class IC or III antiarrhythmics (typically amiodarone for atrial fibrillation) before the procedure. Some patients are advised to take antiarrhythmic therapy after successful cardioversion to reduce the risk of recurrent arrhythmias.

## Preparation

Due to the need to sleep, electrical cardioversion must be performed on an empty stomach (the patient does not eat or drink from midnight, at least 6 hours before the procedure). No other special treatment is required for arrhythmias lasting up to 48 hours. We must reduce the risk of Thrombosis and Thromboembolism for arrhythmias lasting more than 48 hours or of unknown age. The patient at least 3 weeks before the procedure **anticoagulants** warfarin (target INR 2.0-3.0) or NOAC representatives. Anticoagulation also occurs for at least another 4 weeks after cardioversion due to "stunning" of the left atrium. The stated durations of anticoagulation are determined arbitrarily based on certain pathophysiological assumptions (the thrombus dissolves or adheres sufficiently to the atrial wall before its mechanical function is restored) and according to observational data (although thrombi often dissolve for more than three weeks). Anticoagulation at least 3 weeks incidence of complications minimal).<sup>[3]</sup> In high-risk patients, anticoagulant therapy continues even when the sinus rhythm returns. It is advisable to perform before electrical cardioversion **Transesophageal echocardiography** to rule out the presence of intracardiac thrombosis (mainly in the left atrial appendage). Thanks to this examination, it is possible to shorten the required anticoagulation time, and in addition it brings greater security of the parties to the safety of the operation for the patient. If esophageal echocardiography reveals the presence of a thrombus, we must anticoagulate the patient for another 3 weeks and then repeat the echocardiography. When the thrombus dissolves, we can perform cardioversion (these patients are followed by lifelong anticoagulant therapy). It is also necessary to examine the levels of electrolytes.

## Complication

The complications of electrical cardioversion are **rare** (upto 1 %). Rarely, an electric shock can cause ventricular fibrillation instead of interrupting the pathological rhythm. Both doctors (anesthesiologist and cardiologist) must take this complication into account and be prepared to deal with it immediately (usually with a new electric shock of higher energy). Another complication may be embolization of the blood clot, but this is a risk that persists throughout atrial fibrillation. In addition, this is significantly reduced by performing esophageal echocardiography and adequate anticoagulant treatment before the procedure.

## Links

### related articles

- Atrial fibrillation
- Atrial flutter
- Radiofrequency catheter ablation
- Defibrillation

### External links

- Kardioverzia a vulnerabilná perióda (TECHmED) (<https://www.techmed.sk/fenomen-r-na-t/>)

### Source

- ŠTEFÁNEK, Jiří. *Medicine, diseases, study at the 1st Faculty of Medicine, Charles University* [online]. ©2008. [cit. 2.2.2011]. <<https://www.stefajir.cz/index.php?q=electrical-cardioversion>>.

## Reference

1. MARCIÁN, Pavel, Bronislav KLEMENTA a Olga KLEMENTOVÁ. Elektrická kardioverze a defibrilac. Interv Akut Kardiol [online]. 2011, roč. 10, vol. 1, s. 24-29, dostupné také z <<http://www.iakardiologie.cz/pdfs/kar/2011/01/05.pdf>>. ISSN 1803-5302.

2. LIBBY, Peter. Braunwald's Heart Disease : A Textbook of Cardiovascular Medicine. - vydání. Saunders, 2011. 1961 s. s. 805. ISBN 9781437727081.

3. MAYET, J. Anticoagulation for cardioversion of atrial arrhythmias. European Heart Journal. 1998, roč. 4, vol. 19, s. 548-552, ISSN 0195-668X. DOI: 10.1053/euhj.1997.0509.

### Used literature

- ASCHERMANN, Michael. *Cardiology*. 1. edition. Galen, 2004. pp. 1183-1185. ISBN 80-7262-290-0.
- NOT USED, Peter. The role of cardioversion in the treatment of atrial fibrillation. *Cardiological Review* [online]. 2002, vol. 2, p. 109-113, Available from <[http://www.kardiologickarevue.cz/pdf/kr\\_02\\_02\\_09.pdf](http://www.kardiologickarevue.cz/pdf/kr_02_02_09.pdf)>. ISSN 1801-8653.
- Institute of Clinical and Experimental Medicine. *Electrical cardioversion* [online]. [cit. 2011-02-02]. <<https://www.ikem.cz/www/cs/>>.
- MAYET, J.. Anticoagulation for cardioversion of atrial arrhythmias. *European Heart Journal*. 1998, y. 4, vol. 19, p. 548-552, ISSN 0195-668X. DOI: 10.1053 / euhj.1997.0509 (<http://dx.doi.org/10.1053+%2F+euhj.1997.0509>).
- <https://accessmedicine.mhmedical.com/content.aspx?bookid=1872&sectionid=146979876>
- [https://www.uptodate-com.ezproxy.is.cuni.cz/contents/atrial-fibrillation-cardioversion?search=Atrial%20fibrillation:%20Cardioversion&source=search\\_result&selectedTitle=1~150&usage\\_type=default&display\\_rank=1](https://www.uptodate-com.ezproxy.is.cuni.cz/contents/atrial-fibrillation-cardioversion?search=Atrial%20fibrillation:%20Cardioversion&source=search_result&selectedTitle=1~150&usage_type=default&display_rank=1)
- [https://www.uptodate-com.ezproxy.is.cuni.cz/contents/antiarrhythmic-drugs-to-maintain-sinus-rhythm-in-patients-with-atrial-fibrillation-recommendations?search=Atrial%20fibrillation:%20Cardioversion&topicRef=1025&source=see\\_link#H577201755](https://www.uptodate-com.ezproxy.is.cuni.cz/contents/antiarrhythmic-drugs-to-maintain-sinus-rhythm-in-patients-with-atrial-fibrillation-recommendations?search=Atrial%20fibrillation:%20Cardioversion&topicRef=1025&source=see_link#H577201755)
- eCardio.cz chapters Atrial fibrillation (author R. Čihák), Supraventricular tachycardia (B. Aldhoon)
- <https://accessmedicine.mhmedical.com/content.aspx?bookid=1944&sectionid=143522317#1136419271>
- <https://acls-algorithms.com/synchronized-and-unsynchronized-cardioversion/>

- 
- 
-