Dunbar's syndrome

Dunbar's syndrome (celiac artery compression syndrome, ligamentum arcuatum medianum syndrome) is a rare vascular anomaly that results from the oppression of the truncus coeliacus by the ligamentum arcuatum medianum and manifests itself with indigestion. This syndrome remains a diagnosis per exclusion that occurs in only about 2 in 100,000 patients with unclear abdominal pain. [1] thumb | right | 250x250px | Ligamentum arcuatum medianum surrounding the aorta

Etiology

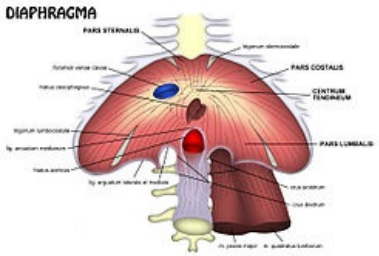

Ligamentum arcuatum medianum surrounding the aorta

The ligamentum arcuatum medianum is a fibrous arch lining the hortus aorticus, which is formed by crossing the crus dexter et sinister. The ligament usually passes above the exit point of the coeliac truncus from the aorta, but in 10-24% of people it crosses the anterior truncus and can cause compression, thereby reducing blood flow through the arteries leaving the trunk and supplying the organs of the digestive tract. Oppression is typically less noticeable in inspiration, where the truncus moves slightly caudally as the lungs expand. When exhaling, the compression then increases. Exhalation of truncus coeliacus during exhalation may be clinically silent due to the development of collateral flow. However, severe stenosis persists even when inhaling and leads to a clinical manifestation of oppression.

Clinical picture

Dunbar's syndrome usually manifests as pain after eating. Mostly it's pressure, a sharper sting, but cramps can also occur. Oppression causes the patient to feel satiated even if they do not eat. The result is significant weight loss and a lack of hunger. As these symptoms are very non-specific, this syndrome is often forgotten and the problem is attributed to other diseases.

Links

related articles

- Diaphragm
- Truncus coeliacus

Resources

-

AL-TUBAIKH, Jarrah. Internal Medicine: An Illustrated Radiological Guide. 2nd edition. Springer International Publishing, 2007. 592

Reference

Foertsch T, Koch A, Singer H, et al. Celiac trunk compression syndrome requiring surgery in 3 adolescent patients. J Pediatr Surg 2007; 42: 709-13.

pp. ISBN 9783319397467.

Template:Pahýl