

Developmental hip dysplasia

Developmental dysplasia of the hip (DDH) hip is a continuous series of disabilities from the lightest dysplasias to severe dislocations of the hip joint. It is also a predisposition to secondary coxarthrosis.

Occurrence

- **most common** congenital defect in children
- incidence in our population - 3%, true dislocation 0.3%
- more often in **girls** (3-5x, more sensitive to the effects of relaxin)
- seasonal incidence (more often in the winter months), racial incidence (rare in blacks)

Etiology

It is probably **multifactorial**, both endogenous and exogenous influences are applied. The following are particularly affected:

1. acetabular development
2. development of the proximal femur.
3. laxity of the joint capsule (i.e. joint hypermobility)

There are a number of theories, none of which are universally accepted, but neither have they been disproved:

- **first defect theory** (theory of heredity) - polygenic recessive genes affect acetabular dysplasia, monogenic dominant genes capsule dysplasia, syndromes (Ehlers-Danlos, Marfan, Larsen etc.), laxity of the hip joint caused by maternal hormones
- **theory of the intrauterine position of the fetus** - DDH develops as a result of increased torsion of the proximal femur and inclination of the socket (sum of both angles $> 60^\circ \rightarrow$ DDH occurs), breech birth (knees in hyperextension, hamstrings pull the femur out of the socket), the divided luxations into teratological and anthropological (i.e. in otherwise normal children, only in them can full success be achieved with treatment)
- **elongated capsule theory** - on a hormonal basis
- **maternal infection theory** (especially viral infection in pregnancy)
- **theory of endocrine disruption**
- **muscle theory**
- **theory of seasonal occurrence** (statistically)
- **changes in the neck** (Zahradníček)
- **theory of the relationship between the size of the fetus and the womb**
- **postpartum mechanical factors - hence developmental dysplasia - main cofactor position in the extensional adduction link DK, head/trunk posture asymmetry and DK, lateral predilection.**

Anatomy

The development of the hip joint begins between the 3rd and 6th week of intrauterine life:

- **Antetorsion of the neck** - in adults finally between $12-15^\circ$
- **CD angle** (collodiaphyseal - angle between neck and diaphysis) - around 150° at birth (so-called physiological valgus), around 130° in adulthood
- **acetabular anteversion** - 2° retroversion to 14° anteversion, meaning of the iliopsoas muscle
- **ossifying core of femur** - appears from 3rd-10th months
- **Y-cartilage and cartilage of the greater trochanter** - disappear around 13th-14th years of age

Pathological Anatomy

DDH is a continuous series of pathological changes from the lightest to the most severe degrees.

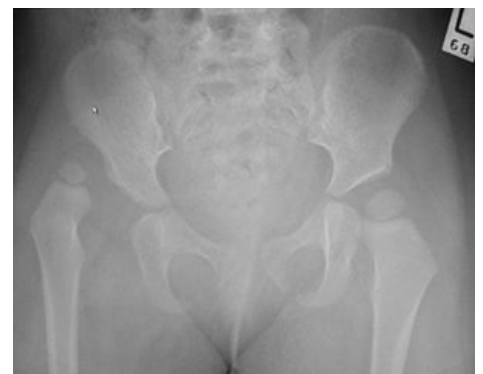- **acetabulum** - tends to be deformed in front, there may be eversion of the labrum, the bony + cartilaginous part of the acetabulum is broken, the dislocation is directed ventrally and proximally
- **neck of the femur** - antetorsion associated with valgus, pressure change on the edge of the acetabulum

DDH grades at birth according to Dunn:

1. degree - positional instability

2. degree - subluxation

3. degree - luxation - significant deformation of the acetabulum, significant anteversion, inversion of the limbus, stretched ligamentum teres and ligamentum transversum, changes on the



X-ray image of DDH.

capsule and joint incongruent, in the further course the pressure on the head increases, the joint capsule continues to lengthen and relax, it can even fuse with the head, there are changes to the limbus, the ligamentum capitis femoris lengthens, the pulvinar increases, neck valgus and anteversion increase, the head tends to be smaller

- **muscles** – shortened, but the most changed is the iliopsoas muscle, kt. it is pulled out by the head and cuts into the capsule, where it creates an isthmus and a so-called hourglass-shaped capsule

Isolated dysplasia of the acetabula does not cause dislocation or subluxation of the hip, we distinguish between 4 degrees of acetabular dysplasia:

- 1. grade** – the acetabulum is normal, only the lateral edge is not fully developed
- 2. grade** – already a steep roof
- 3. grade** – oval acetabulum, vertically elongated
- 4. grade** – the acetabulum is flat, the neocotyl (neoacetabulum) is already developed, in which the head of the femur is

There is always a lengthening of the ligamentum teres, a hypertrophic pulvinar and a slowing of the ossification of the epiphysis of the proximal femur, resulting in a long valgus neck with great anteversion.

Investigative Methods

1. clinical examination
2. sonography of children's hip joints according to Graf
3. X-ray examination

Clinical examination

Anamnesis records the course of the pregnancy - first or repeated, whether the mother was ill (mainly viruses), did she undergo radiation exposure, etc., we look for the presence of DDH and other congenital orthopedic defects in the family and extended relatives. During **own clinical examination** we follow:

- **Position of the lower limbs** - pathological great flexion and abduction / adduction in the hips, asymmetry of the holding of the limbs
- **muscle tone**
- **movement of limbs** - limitation of abduction on one or both sides
- **depth of the adductor fossa** - palpation of the joint head in the fossa
- **asymmetry of thigh grooves**
- **asymmetry of the gluteal grooves** in the prone or hanging position
- the presence of **scoliosis**
- **we palpate the greater trochanter** in the prone position - there should not be too much free movement
- **Bettman's sign** - at 90° flexion in the knees and hips, the knee on the luxated side is lower
- **Ortolani's sign** - when moving the limb into abduction and flexion, there will be skipping and snapping (reposition of the head into the socket of the hip joint), never do it with force (so as not to traumatize the luxated head)
- **Trendelenburg's sign** - in older children, pelvic drop when standing on 1 leg

Sonography

It does not replace X-ray examinations, but can minimize them.

The **Triple Sieve System** (according to Prof. Graf) includes clinical and sonographic examination:

- **1. stage** (3rd-5th day after birth) - in the maternity hospital - first clinical examination, then sonographic examination, linear probe 5-7.5 MHz, from the maternity hospital it is necessary to pay attention to the correct packing of newborns (preventive abduction)
- **2. stage** (at the end of six weeks, 6-9 weeks) - in the orthopedic clinic - clinical + sonographic examination, the most unstable and dysplastic hips are detected around the 6th week of age + it is necessary to start treatment immediately
- **3. stage** (weeks 12-16) - clinical + sonographic examination, in case of unclear findings we will supplement X-ray

Rating by Chart

During the examination, we use auxiliary lines:

- **baseline** - identical to the hip bone echo
- **line of the bone edge of the acetabulum** - a straight line passing through the lower edge of the hip bone and the inflection point (promontorium) / top of the bone roof
- **cartilaginous roof line** - connects the inflection point + the center of the labrum
- **angle α** (bone cap angle) - the angle that the base line makes with the bone cap line, normally 60° or more
- **angle β** (corniceal angle) - the angle that the base line makes with the cornice line, normally 55° and less
- **head centering** - correct if the greater part of the head is medial to the baseline

We divide the findings into the following groups:

- **type I** - a normal finding regardless of age
- **type II - stable dysplasia** - the most widespread form of DDH, centered hip joint with rounded bone edge, angle α is 50–59° and β is greater than 55°, extend the abduction wrap (or Frejko's blanket) until the sonographic findings normalize
- **type III - decentred hip joint** - insufficiently developed bone and cartilaginous roof, hip decentred and head proximalized, angle α cannot be measured, distraction mode, we verify X-ray examination
- **type IV - most severe** - often ends in open reduction, immediate distraction mode

X-ray examination

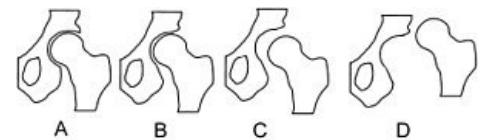
Determination of angles and auxiliary lines:

- **Hilgenreiner line** - line connecting the centers of the Y-cartilages
- **roof angle** (AC angle) - between the junction of the edges of the acetabulum and Hilgenreiner's line, at the age of 3-4 months the norm is up to 30°, higher pathological
- **Shenton-Ménard line** - an imaginary curve running along the neck of the femur + smoothly transitioning to the medial edge of the upper ramus of the pubic bone
- **Hlavinkova line** - an imaginary curve passing through the outer edge of the iliac blade and the outer edge of the neck of the femur
- **Ombredann-Perkins vertical** - a line running from the outer edge of the acetabulum perpendicular to Hilgenreiner's line
- Kopitz's parallelogram (the so-called square of certainty) - the lower side is formed by the upper edge of the epiphyseal line of the femur and the upper side by the lines of the roof, in pathological conditions a diagonal quadrilateral

File:Rtgdysplasia.png
X-ray orientation line

According to X-ray findings, we divide DDH into several groups:

- **preluxation** (acetabular dysplasia) - only a steep roof and an increase in the AC angle (from 30-35°), clinical findings are normal, the head is well centered, therapy: abduction packing
- **subluxation** - in addition to the AC angle (greater than 30°), Shenton's and Hlavinka's lines are also broken, the upper end does not exceed Hilgenreiner's line, therapy: Frejka's pillow or Pavlík's stirrups, follow up after 1-3 weeks
- **marginal luxation** - short, steep cap, the head presses on the germinal layer of the cartilaginous cap and labrum → leads to acetabular dysplasia, Shenton and Hlavinka's lines are broken, Kopitz's parallelogram is significantly oblique, therapy: hospitalization - distraction + spike or surgery
- **luxation** - nucleus in the upper outer quadrant, lateralization of the head, broken Shenton's and Hlavinka's lines (passes through the medial edge of the femur), clinically shunt and asymmetry of the limb, empty joint fossa, limitation of abduction, the finding is most striking in the so-called "frog position" (on the stomach with flexion of the limbs at the knees and hips, it is not possible to luxoduct the affected side - the limb is in greater or lesser extension), therapy: hospitalization - distraction and spica or surgery



Scheme of degrees of hip dysplasia.

Therapy

Conservative therapy

Tools used for conservative treatment:

- **simple abduction wrap** - we use it as a prevention until at least 6 weeks of age, when we find the most dysplasias, then for preluxations
- **abduction Frejko's pillow or Pavlík's stirrups** - for subluxations and preluxations after the 16th week of age, until the ossification core of the femur appears
- **distraction mode** - during hospitalization, in case of marginal and iliac dislocation, the frame is part of the infant bed
 - distraction is carried out according to the set schedule and curtain system
 - we only use positions where blood supply to the head is not at risk (safe zone) - hip flexion in the range of 90-120°, abduction 50-70°, the stable zone is the area where the hip is centered and is stable (always within the range of the safe zone)
 - distraction takes place 24 hours a day, we only take the child for feeding + hygiene
- reposition is verified sonographically, radiologically and clinically, to rule out a repositioning obstacle we perform arthrography
- if the repositioning is verified and repositioning obstacles are ruled out, we start the retention phase of treatment - applying a plaster spike in the safe zone for at least 6 weeks, then we scan and after an X-ray and SONO check, we put on an abduction device
- danger of aseptic necrosis of the head → we check X-ray as a rule once every 8 weeks, ultrasound check can be more frequent



Frejka's duvet

- if we find a repositioning obstacle, we operate

Operational therapy

4 basic types of DDH operations:

1. open (bloody) reduction (unilateral up to adolescent age, bilateral up to 10 years)
2. extra-articular operations on the proximal femur
3. pelvic osteotomy or acetabuloplasty
4. combination of these procedures (e.g. Salter's pelvic osteotomy + varis osteotomy of the femur)

Reposition obstacles:

- *extra-articular* (joint capsule stricture) – shortened m. iliopsoas, adductors, gluteus medius
- *intracapsular* – inverted limbus, pulvinar acetabuli, residual lig. transversum acetabuli etc.

It is a repositioning operation, with the opening of the joint capsule, articulation and subsequent plaster fixation. Different types of **operational approaches** (frontal or medial)

- if large anteversion is present → attached subtrochanteric osteotomy with femoral abbreviation



Pavlik's stirrups

After 18 months of age, the shallow acetabulum is no longer able to hold the repositioned head in the socket → it is necessary to attach a **pelvic osteotomy** (overarching operation):

- **Salter's pelvic osteotomy** (after 18 months of age) – correction of misalignment of the acetabulum so that the hip is stable in a functional position, the osteotomy is performed supraacetabular, a saw is inserted into the incisura ischiadica, after cutting through the pelvis a graft from the hip blade is inserted into the osteotomy → the acetabulum folds forward and laterally → the angle of the roof changes, the head is stable in the hip after articulation, advantage: the acetabulum and its cartilage are preserved (physiological conditions in the joint), the operation also lengthens the limb by thickness inserted graft
- **Pemberton's osteotomy** – the osteotomy did not penetrate into the sciatic notch, the grafts were not fixed with metal material
- **Steel's triple osteotomy** (over 6 years) – osteotomy of all 3 pelvic bones around the acetabulum, adjustment of the position of the acetabulum to a preselected position and transfixation with Kirschner wires, demanding operation
- **Chiari osteotomy** – horizontal osteotomy with medial insertion of the distal fragment → roofing occurred on the outer side above the hip joint

Healing Consequences Operation:

- **extra-articular transposition of the greater trochanter** – the overgrown and highly attached greater trochanter is cut off, fixed about 3 cm more distally, and its apophyseodesis is connected at the same time

Isolated procedures in the area of the proximal femur:

- **valgizing** or
- **variational**
- **derotational osteotomy**

Complications of therapy and residual defects

- aseptic necrosis of the femoral head (7%) with changes in the shape of the head (coxa plana, coxa vara with overgrowth of the greater trochanter, coxa magna)
- shape deviations of the acetabulum
- changes in CD angle and antetorsion angle

Links

Related Articles

- Congenital limb defects
- Congenital shin splints
- Proximal focal femoral deficiency
- Trendelenburg sign

Use literature

- KOUDELA, K., et al. *Ortopedie*. 1. edition. Prague : Karolinum, 2004. ISBN 80-246-0654-2.
- SOSNA, A. – VAVŘÍK, P. – KRBEC, M., et al. *Základy ortopedie*. 1. edition. Prague : Triton, 2001. ISBN 80-7254-202-8.
- DUNGL, P, et al. *Ortopedie*. 1. edition. Prague : Grada Publishing, 2005. ISBN 80-247-0550-8.