

Dermatofibrosarcoma protuberans

Dermatofibrosarcoma protuberans is a malignant fibrous tumor, characterized by local invasion and frequent recurrence. The tendency to metastasize is small.

Clinical picture

It occurs as a rigid bump on the upper body. During development, they form as painful brownish-red or bluish bumps with vascular ectasia on the surface. The tendency for infiltrations of the lower layers of the skin is relatively common. It metastasizes exceptionally to regional nodes or lungs.

Diagnosis

Histopathologically, it contains CD34 + fibroblasts in a typical storiform arrangement.

Differential diagnosis

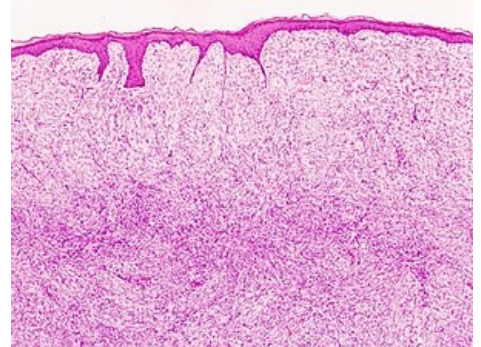
- Keloids
- Dermatofibroma
- Fibrosarkom

Therapy

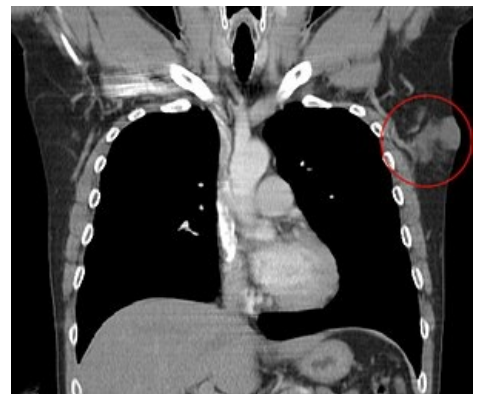
Surgical removal with a wide margin of at least 3-5 cm into healthy tissue and to a depth of fascia.

Prognosis

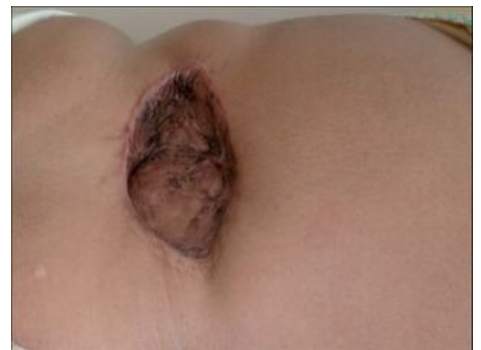Chronic course, frequent recurrences after surgical treatment. Metastasizes rarely.



Histological picture of dermatofibrosarcoma protuberans



CT, dermatofibrosarcoma protuberans in the left axilla



Dermatofibrosarcoma protuberans