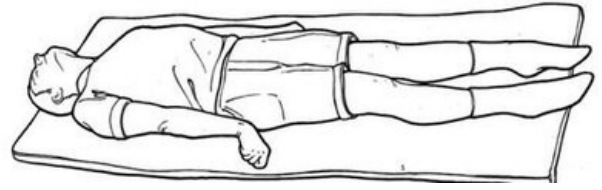


# Decerebrate rigidity



**Decerebrate rigidity** arises from a bilateral lesion **at the level of mesencephalon** or **caudal diencephalon**. It is the result of removing the influence of the inhibitory part of the descending reticular formation. This will increase the tone of the extensors. Rather than rigidity, this is *extension spasticity*. Upper limbs are *extended*, the forearm is in pronation, the wrist is in flexion. The lower limbs are *extended*. Opisthotonus may occur.<sup>[1]</sup>



Decerebrate position

## Links

### Related articles

- Decorticate rigidity

### References

1. AMBLER, Zdeněk. *Základy neurologie*. 6. edition. Praha : Galén, 2006. 351 pp. ISBN 80-7262-433-4.

### Used literature

- AMBLER, Zdeněk. *Základy neurologie*. 6. edition. Praha : Galén, 2006. 351 pp. ISBN 80-7262-433-4.