

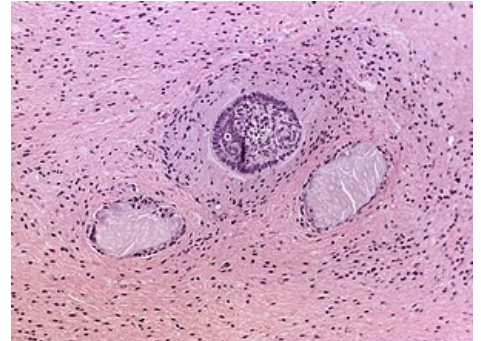
# Craniopharyngioma

**Craniopharyngioma** is the second most common tumor in the sellar region (the first is pituitary adenoma). It represents about 4% of intracranial tumors, 50% of them in children - most often between 10-15. year. It grows out of the remnants of Rathke's cysts, often reaching high into III. ventricle of the brain. The tumor is biologically **benign**, but may be malignant due to its location and relationship to vital structures such as the hypothalamus, blood vessels, *optic chiasm*.

It almost always has two components - solid and cystic.

## Clinical picture

- Compression of the visual pathway, loss of visual field from pressure on the optic chiasm.
- Obstructive hydrocephalus during propagation into the ventricles.
- Hormonal disorders of oppression of the hypothalamus and the pituitary gland.
- intracranial pressure may be increased in larger tumors .



Histological specimen

## Diagnosis

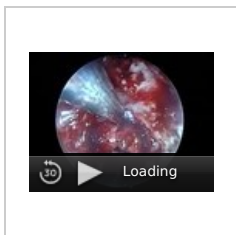
- MRI.
- CT – bounded formation with calcifications.

## Differential diagnosis

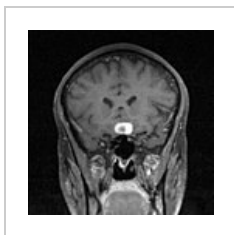
It is facilitated by the fact that, unlike adenomas they are usually cystic and calcified.

## Therapy

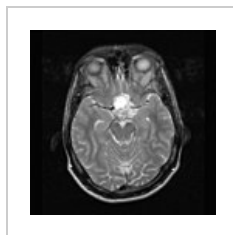
- Primarily **surgical** – usually subfrontally, compared to adenomas, it is removed much worse because it fuses with the formations around. Therefore, the operation is often not radical and the tumor recurs (it can be irradiated, but in children it is complicated).
- **Radiotherapy** – we completely irradiate incompletely removed tumors with small fields, which are targeted only at the tumor area. The total dose is about 50-55 Gy in 5-6 weeks.



Endoscopic operation of the cranial base - Intraseptal craniopharyngioma



MRI sagittal section



MRI axial section

## Link

### related articles

- Pituitary adenoma

### Source

- ws: Kraniopharyngioma
- -. - : *Studijní materiály* [online]. ©2010. The last revision -, [cit. 2009]. <<http://jirben.wz.cz>>.

### References

- ZEMAN, Miroslav, et al. *Speciální chirurgie*. 2. edition. Praha : Galén, 2004. 575 pp. ISBN 80-7262-260-9.
- SAMEŠ,, et al. *Neurochirurgie : Učebnice pro lékařské fakulty a postgraduální studium příbuzných oborů*. 1. edition. Praha : Maxdorf, 2005. 127 pp. pp. 79. ISBN 80-7345-072-0.
- PETRUŽELKA, Luboš – KONOPÁSEK, Bohuslav. *Klinická onkologie*. 1. edition. Praha : Karolinum, 2003. 274 pp. ISBN 80-246-0395-0.

Template:Navbox - nádory CNS