

Congenital malformations of the auricle

Classification of deformities according to Roger

- **microcia** (hypoplasia of pinna)
- **overhanging bolt** (lop ear)
- **cone-shaped ear** (cup ear)
- **retired bolter (otapostasis)**

Classification according to Tanzer

- **Anocia** (complete absence of pinna)
- **complete hypoplasia** (microcia) with / without atresia of the external auditory canal
- **hypoplasia of the middle 1/3 of the ear**
- **hypoplasia of the upper 1/3 of the ear:** "constricted ear" (overhanging pinna + cone-shaped ear), cryptoclia, hypoplasia of the entire upper 1/3
- **removed bolts**

Other deformities

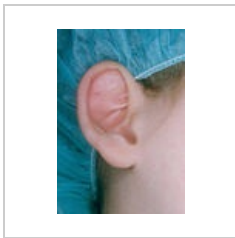
- **appendices praeauriculares** (rudimentary growths around the pinna)
- **fistulas** incomplete (lead a short distance) / complete (lead to the mouth or pharynx)

Associated diseases

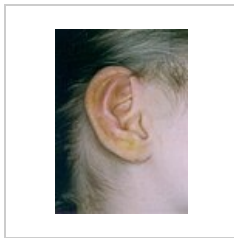
- **hearing disorders** based on anomalies of the middle ear, developmental disorders of the inner ear, hereditary disorders of cochlear development
- **hemifacial microstomia**
- **urinary tract anomalies**

Treatment

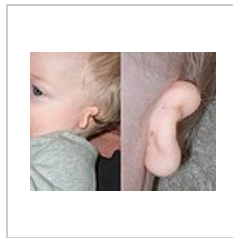
- operation changing the shape of the cartilaginous part of the auricle → change of soft tissues.
- most often surgery for detached auricles
- in case of non-development of the auricle, we reconstruct the cartilaginous part with cartilage from the rib + soft tissue by tissue expansion and local displacements



Otapostasis



Antihelix after reconstruction



Microtia

Links

Related Articles

- Congenital defects of the external and middle ear
- Acquired Bolt Defects

References

- MĚŠŤÁK, Jan, et al. *Úvod do plastické chirurgie*. 1. edition. Praha : Univerzita Karlova v Praze - Nakladatelství Karolinum, 2005. 125 pp. ISBN 80-246-1150-3.