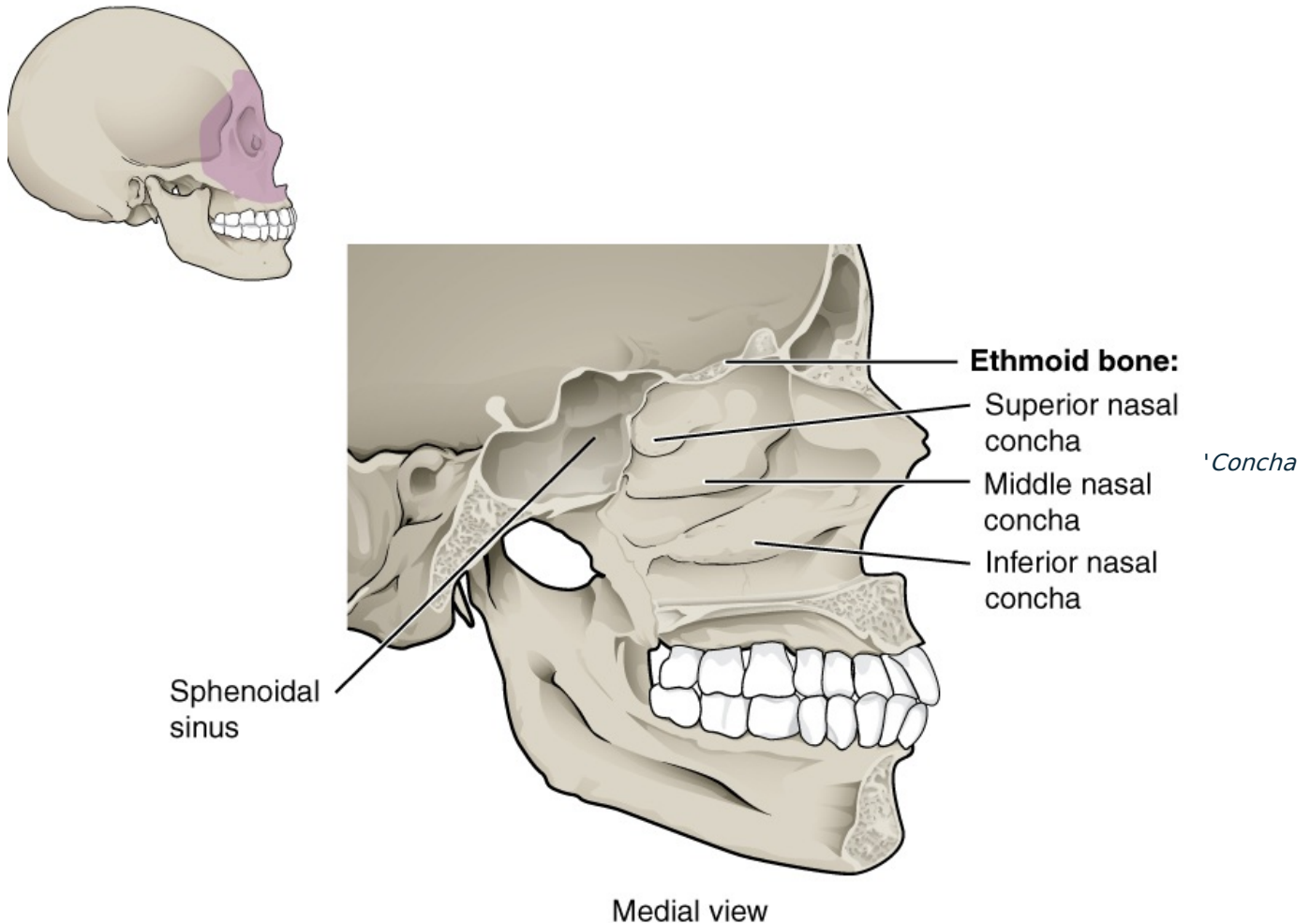


Concha nasalis inferior



nasalis inferior is a thin flat bone, similar in shape to the *concha nasalis media*, slightly larger, similarly arched and its upper edge fixed to wall nasal cavity.

The **Processus maxillaris** is a curved projection on the cranial side, by which the concha joins the *facies nasalis maxillae* in the sutures so that it completes this surface. It makes the team less of a hole that it is *sinus maxillaris* associated with *cavitas nasi*.

From the upper edge of the concha still protrudes:

- **processus lacrimalis** - a small protrusion forward upwards for connection with the *os lacrimale*; by attaching to the upper jaw and to the lacrimal bone, it co-creates the wall of the bony "canalis nasolacrimalis";
- **processus ethmoidalis** - projection backwards up for connection with the *processus uncinatus conchae mediae*.

Related Articles

- Nasal cavity

References

- ČIHÁK, Radomír – GRIM, Miloš. *Anatomie*. 2. edition. Grada Publishing, 2002. 470 pp. vol. 1. ISBN 80-7169-970-5.