

Chronic Otitis Media

Chronic otitis media (*Otitis media chronica suppurativa, OMC*) is characterized by:

- eardrum perforation,
- long-term secretion from the middle ear,
- attenuated pneumatization of the temporal bone,
- varying degrees of conductive hearing loss.

Contributing factors

- **Local** - VVV in HCD (mainly cleft palate), long-term disorders of the ventilation function of the auditory tube (adenoid vegetation);
- **General** - immune defects (mainly IgA classes, allergies, diabetes mellitus, CF, cardiovascular malformations).

Classification

2 basic forms according to the location of the pathological process:

1. OMC mesotympanalis (simplex, catarrhalis),
2. OMC epitympanalis.

Otitis media chronica suppurativa mesotympanalis

This type of inflammation arises on the basis of relapses of acute inflammation or, more often, by the transformation of latent inflammation. The inflammation affects the mucous membrane of the tympanic cavity, but is usually not a source of complications. The main causes are insufficient treatment of the primary disease and protracted inflammation of HCD. Thanks to ATB, the frequency of chronic inflammation is lower. In case of chronic inflammation, the mucous membrane is repeatedly hypertrophied, the epithelium changes to cylindrical with cilia and goblet cells. In addition, ear polyps and granulations grow on the mucous membrane.

Etiology: most often *pseudomonas aeruginosa*, *staphylococcus aureus*, *proteus*, *escherichia coli*, *klebsiella*.

Otoscopic picture: There is a central perforation of various sizes in the pars tensa of the eardrum, where the edges are epithelized and therefore spontaneous healing is not possible. The perforation reveals a view of the promontory, the annulus tympanicus is always preserved.

Clinical picture:

- moderate conductive hearing loss,
- *discharge from the ear* - purulent, odorless,
- temperature and pain are absent.
- **Microbiology** - often mixed flora - *escherichia*, *klebsiella*, cocci, *proteus*, *pseudomonads* and fungi.

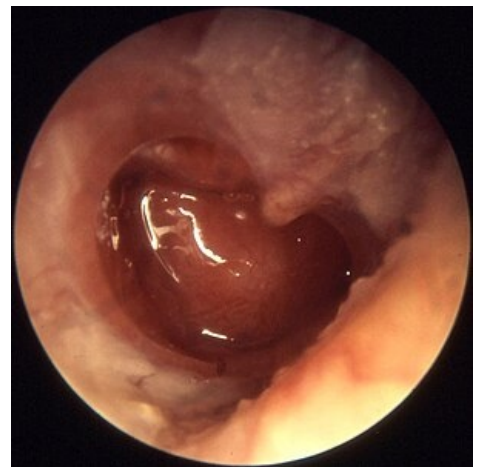
Treatment: Continuous treatment of all HCD inflammations, improvement of nasal patency and restoration of tubal function is key. Local administration of ATB based on sensitivity is also suitable, possibly in combination with corticoids (the combined preparation InfaIn duo contains fluocinolone and ciprofloxacin). Polyps and granulations are surgically removed, and after microflora eradication, myringoplasty can be performed in 3 months.

Prognosis: it is favorable, residues after inflammation can be solved surgically.

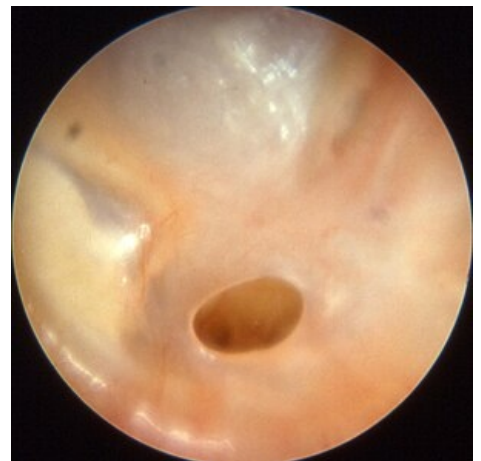Complications: they are rare, most often inflammation of the ear canal.

Otitis media chronica suppurativa epitympanica

In the case of chronic epitympanic inflammation, the causes are not yet fully understood. There is no history of HCD or acute otitis media. The classic form takes place in the epitympanum, while the mesotympanum is free. Part of the finding is also damage to bone structures, especially in the form with the formation of cholesteatoma, which is locally aggressive. The pars tensa is preserved intact and the Eustachian tube is functional. The pars flaccida of



Otitis media chronica mesotympanalis



Otitis media chronica mesotympanalis

the eardrum is affected. Cholesteatoma occurs in practically every inflammation of this type and destroys the walls of the cavity. Cholesteatoma is made up of squamous keratinized epithelium and has enzymes on its surface that are the cause of the destruction of the surroundings.

Etiology: often anaerobic – Bacteroides, Peptococcus.

Symptoms: they are creeping, the patient complains of hearing loss; scanty but foul-smelling discharge from the ear; but pain and temperature are absent.

Otoscopic image: perforation with granulation tissue or cholesteatoma, where polyps grow from the edges.

X-ray: muted pneumatization with signs of sclerotization of the temporal bone.

Treatment: surgical only - the sooner the better.

Dangerous complications: disorder of N. VII ; penetration into the labyrinth or intracranially.

Otitis media chronica suppurativa mesoepitympanalis

It is a combination of the previous types of inflammation and an atypical cholesteatoma is formed in it.

Links

Related Articles

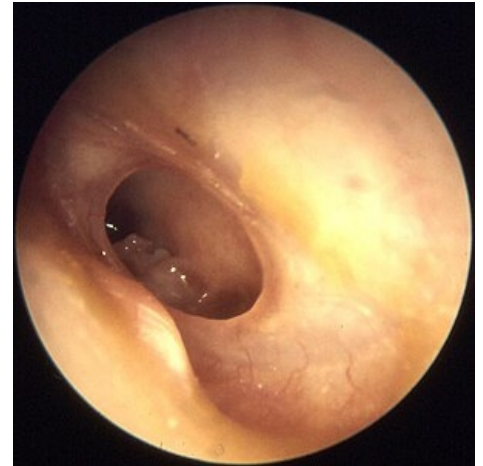- Inflammation of the middle ear
- Acute otitis media
- Acute tubotympanic catarrh
- Secretory otitis
- Classification of otitis media
- Complications of otitis media
- Recurrent otitis media
- Cholesteatoma

Source

- BENEŠ, Jiří. *Studying materials* [online]. ©2007. [cit. 2009]. <http://jirben2.chytrak.cz/materialy/orl_jb.doc>.

References

- KLOZAR, Jan. *Special otorhinolaryngology*. 1. edition. Galén, 2005. 224 pp. ISBN 80-7262-346-X.
- HRODEK, Otto – VAVŘINEC, Jan. *Pediatric*. 1. edition. Galén, 2002. ISBN 80-7262-178-5.
- ŠAŠINKA, Miroslav – ŠAGÁT, Tibor – KOVÁCS, László. *Pediatric*. 2. edition. Herba, 2007. ISBN 978-80-89171-49-1.



Otitis media chronica mesotympanalis